CSECLS 2022

汇聚创造无限可能

Together We Can

第6届中国医师协会体外生命支持年会

The 6th Chinese Society of ExtraCorporeal Life Support Annual Meeting

2022年6月18日-19日　线上直播

优秀壁报

论文全文

- Veno-Venous Extracorporeal Membrane Oxygenation for Severe Acute Respiratory Distress Syndrome Following Chlamydia Psittaci Infaction: A Case Report and Literature Review
- Successful treatment of near-fatal asthma with ECMO: A case report and literature review
- Extracorporeal Membrane Oxygenation Using a Modified Cardiopulmonary Bypass System
- Venovenous extracorporeal membrane oxygenation during pregnancy: a case of severe pneumonia complicated with severe acute respiratory distress syndrome
- Treatment of malignant airway stenosis with extracorporeal membrane oxygenation under low-dose anticoagulation: a case report
- 体外膜肺氧合治疗院外心脏骤停1例
- VA-ECMO用于运动神经元病合并脓毒症休克的治疗1例
- 体外膜肺氧合救治1例急性爆发性心肌炎患儿的护理

论文摘要

- Serum total bilirubin with hospital survival in adults during extracorporeal membrane oxygenation
- Intensivist-led transportation of patients on extracorporeal membrane oxygenation: a single center experience
- Analysis of risk factors affecting the prognosis of cardiogenic shock assisted by venous-arterial extracorporeal membrane oxygenation
- Risk Factors associated with Nosocomial Infection in Patients during Extracorporeal Membrane Oxygenation
- 血管活性药物-正性肌力药物评分及乳酸与成人心脏术后VA-ECMO患者的预后

主办单位：
中国医师协会
中国医师协会体外生命支持专业委员会

协办单位：
中国生物医学工程学会体外循环分会
江苏省医师协会
江苏省医师协会体外生命支持专业委员会

承办单位：
东南大学附属中大医院
首都医科大学附属北京安贞医院

Veno-Venous Extracorporeal Membrane Oxygenation for Severe Acute Respiratory Distress Syndrome Following Chlamydia Psittaci Infaction: A Case Report and Literature Review

Yaowei Tong+, Julaiti Rouzhahong+, Wangtao Zhou, Amanguli Moming, Yuqiang Wang, Hong Lei, Ju Guo, Zhengkai Wang, Ying Li, Yunlin Song*
+ Julaiti Rouzhahong and Yaowei Tong contributed equally to this work.
* Corresponding:1783363502@qq.com
Department of Intensive Care Unit, The First Affiliated Hospital of Xinjiang Medical University,Urumchi 830054, China
Full list of author information is available at the end of the article

Funding project：The State Key Laboratory of Subhigh Disease Pathogenesis and Prevention and Control in China, Study on the diagnostic value of screening diagnostic markers of latent tuberculosis based on Olink technology and their combination with miRNA in the diagnosis of latent tuberculosis, project number: SKL-HID-CA-2021-JH13.

Abstract Background: Infection of Chlamydia psittaci (C. psittaci) could lead to severe pneumonia with rapid progression, acute respiratory distress syndrome (ARDS), sepsis, multiple organ dysfunction syndrome (MODS), and even death. In recent years, Extracorporeal membrane oxygenation (ECMO), as the "ultimate weapon" for life support, has been increasingly applied in the treatment of severe ARDS. However, its use in support of severe ARDS caused by chlamydia psittaci has rarely been reported in critically ill patients.

Case Presentation: We report a 32-year-old man who was diagnosed with Chlamydia psittaci by Metagenomic next-generation sequencing(mNGS). This case was admitted to the hospital with "headache with cough, chest tightness for 10 days" as the main complaint. After admission, he was treated with routine anti-infection, oxygen, and fluid supplements. The condition rapidly progressed to sepsis, severe ARDS, and MODS. Then, he received urgently mechanical ventilation and combined with Prone Position Ventilation(PPV), but his severe hypoxemia was difficult to improve. On the third day of admission, he received venous-venous extracorporeal membrane oxygenation(VV-ECMO) support. After that, his hypoxemia was quickly corrected and hemodynamics gradually stabilized. According to the report provided by MNGS, we adjusted the antibiotic treatment plan to Azithromycin combined with Tigecycline. Subsequently, his condition gradually improved and the ECMO was weaned successfully on the tenth day without any complications. After seven days, he recovered and was discharged.

Conclusion: mNGS is particularly important for the diagnosis of severe atypical pneumonia and guides the application of antimicrobial agents. Chlamydia psittaci as a zoonotic obligate intracellular bacterium, it's infections can result in severe pneumonia, ARDS, sepsis and MODS, and all of them are life-threatening. Thus, when conventional treatments are ineffective, VV-ECMO support should be performed as soon as possible to obtain treatment time for the primary lung lesions. **Keywords**: Chlamydia psittaci, Acute respiratory distress syndrome, Extracorporeal membrane oxygenation, Next-generation sequencing, Case report

BACKGROUND

Chlamydia psittaci (C. psittaci) was first isolated from parrots, and parrots are the most common host, hence the name. It is a kind of aerobic gram-negative bacteria, intracellular parasitic. Parrots, pigeons, poultry, and other birds are the main hosts. The main transmission route is direct contact with infected animals, nasal secretions of birds, infected bird feces, or inhalation of infected birds' feather dust, etc［1］. Human-to-human transmission has not been confirmed［2］. Chlamydia psittaci is distributed worldwide, with a lower incidence in Asia than in Europe and Australia［3］. Chlamydia psittaci infection mostly occurs in young and middle-aged people, most of whom have a history of contact with birds, and the incubation period is usually 5 to 19 days. The clinical manifestations are not typical, ranging from asymptomatic to life-threatening, involving different organs, including the lung, heart, liver, spleen, kidney, central nervous system, etc. The lung is the most commonly affected organ, often presenting as fever, chills, bradycardia, headache, myalgia, cough, chest tightness, dyspnea, etc［4,5,6］. Chlamydia psittacosis pneumonia accounts for about 1% of community-acquired pneumonia(CAP)[7], with a low incidence rate. In addition, most clinical microbiology laboratories have not carried out pathogen detection, so it is easy for clinicians to miss it often resulting in a misdiagnosis. Without a timely diagnosis, it can progress to severe pneumonia, respiratory failure, acute respiratory distress syndrome (ARDS), meningitis, and even multiple organ dysfunction Syndrome (MODS), which can be life-threatening［8］.

In recent years, with the vigorous development of extracorporeal life support (ECLS) technology, Extracorporeal membrane oxygenation (ECMO) has been increasingly used to support critically ill patients with severe respiratory or/and circulatory failure, saving thousands of lives[9,10]. Since 1990, the number of ECMO applications has increased nearly tenfold worldwide with an overall survival rate of 54%. The survival rate of venous-venous (VV) -ECMO for adult ARDS is about 59%, and the number of cases treated by ECMO is increasing by 15% per year[11]. A meta-analysis on the efficacy of VV-ECMO in the treatment of severe ARDS showed that VV-ECMO significantly reduced mortality compared with conventional mechanical ventilation[12]. As the "ultimate weapon" of life support, ECMO has been increasingly used in the treatment of severe ARDS in recent years. It can provide gas exchange, allow the lungs to get adequate rest, and reduce ventilator-induced lung injury (VILI) to obtain treatment time for the recovery of the primary lung lesions. However, its use in the treatment of Chlamydia psittaci infection is rarely reported.

We report a case of a severe ARDS patient who was treated with VV-EMO combined with prone position ventilation(PPV) at a life-threatening moment. Metagenomic next-generation sequencing (mNGS) of cerebrospinal fluid revealed chlamydia psittacis infection. We used azithromycin combined with tigecycline for anti-infective treatment. The lung lesions were quickly cured with the respiratory function gradually recovered. Finally, the patient recovered fully and was discharged from the hospital successfully. Further research and discussion are needed on VV-ECMO in the treatment of Chlamydia psittaci infection.

CASEPRESENTATION

The 32-year-old male patient was admitted to the First Affiliated Hospital of Xinjiang Medical University on November 10, 2021, with "headache, cough and chest tightness for 10 days". Ten days ago, he developed a headache accompanied by a cough, chest tightness, and weakness of the right limb. He gradually developed hallucinations and abnormal behavior, manifested as gibberish, delirium, and increased talk in his sleep. Occasionally, he suffered from wheezing, nausea, and vomiting. Since then, his symptoms have not been alleviated by self-administered ibuprofen and brain tonic. One day ago, he came to the emergency room for treatment with urinary incontinence. He worked as a decorator and had a history of smoking. Physical examination on admission: T: 38.6°C, P: 122 times /min, R: 39 times /min, BP: 90/40 mmHg (1mmHg=0.133KPa), SPO2:66%. Drowsiness, lethargy, the right lung breath sound is clear, the left lung breath sound is weakened, voice tremor is enhanced, percussion is solid sound, Other physical examinations were negative. Due to his unconsciousness and difficulty in breathing, SPO2 continued to decline, and he was given an emergency endotracheal intubation ventilator for assisted breathing. The ventilator parameters are as follows: IPPV mode, FiO2:100%, PEEP:14mmHg; On the day of admission, chest CT showed multiple patchy and large patchy consolidation areas and multiple nodules in both lungs, which was considered as infectious lesions(Fig. 1). The indicators of infection on admission are as follows: WBC 6.16×109/L, NEUT% 91.8%, PCT 42.98ng/mL, CRP >90mg/L, IL-6 1468 pg/ml; The organ function indicators are as follows: Creatinine 163umol/L, total bilirubin 28.35umol/L, AST 1705.35U/L, troponin 0.042ug/L, CK-MB 20.4ng/mL, myoglobin > 2000ug/L, Hb 126g/L, PLT 77×109/L; Blood gas analysis indicators are as follows: FiO2 100%, PH 7.42, PO2 59mmHg, PCO2 26mmHg, BE -7.6mmol/L, HCO3- 16.9mmol/L, Lac 1.3mmol/L, P/F 59mmHg; Fungal D-glucan detection < 37.5pg/ml; Respiratory pathogens nine items (-); On admission day, we collected blood and alveolar lavage fluid culture; The day after admission, we did a lumbar puncture; The cerebrospinal fluid(CSF) was clear and colorless, the pressure of CSF was 250mmH2O, and The Pan's test (-); The total number of white blood cells, sugar, protein and adenosine deaminase in CSF were 3×106/L, 3.9mmol/L, 0.22g/L, and 0.50 U/L; Finally, CSF was collected for mNGS. Primary diagnosis: sepsis, severe community-acquired pneumonia, severe ARDS, MODS (respiratory failure, acute renal insufficiency, acute liver insufficiency), intracranial infection, APACHEII: 25; SOFA: 14; Norepinephrine and fluid were given to maintain circulation stability; Protective lung ventilation strategies, sedation, analgesia, and prone position ventilation(PPV) to improve oxygenation; Anti-infective treatment was empiric with ceftriaxone 2g qd combined with ganciclovir 0.25g q12h; However, after 2 days, his condition gradually deteriorated, presenting progressive aggravation of bilateral lung invasion, continuous increase of infection index (PCT > 100ng/mL) and refractory hypoxemia (SPO2:85%, P/F 62mmHg). We treated the patient with VV-ECMO at 20:00 on November 12, using the Seldinger method and percutaneous catheterization guided by bedside B-ultrasound. Femoral vein and internal jugular vein cannulation were used. A 21F venous cannula(Maquet) was inserted into the femoral vein at a depth of 45cm, with the tip in the inferior vena cava at the entrance to the right atrium for drainage. The oxygenated blood was returned through the internal jugular vein with a 17F arterial cannulation (Maquet) at a depth of 10cm. Its tip is located in the superior vena cava at the entrance to the right atrium. Bedside radiography (X-ray) was taken immediately after catheterization to determine intubation position and to adjust if necessary to minimize "recirculation". The remainder of the ECMO loop consists of a centrifugal pump oxygenator (Maquet PLS membrane lung). After ECMO transition, oxygenation improved rapidly, hemodynamics gradually stabilized and combined with PPV to promote pulmonary recovery (Fig. 2). The MNGS detection results showed: Chlamydia psittaci after the application of VV-ECMO. Therefore, we adjusted the antibiotics to azithromycin 0.5g qd combined with tigecycline 50mg q12h. After that, the infection index gradually decreased, and a chest X-ray showed obvious absorption of lung infection foci in daily review (Fig. 3). His condition improved gradually, and no complications occurred during the period. After 184h VV-ECMO support, ECMO was weaned successfully at noon on November 20(Blood gas analysis results, infection indicators, hemodynamic indicators, and ECMO parameters during the period are shown in Table 2). Tracheal intubation was removed on November 23 after bedside rehabilitation and respiratory function exercise. Re-examination of chest CT on November 25 showed that the large area of consolidation in the left lung was significantly absorbed (Fig. 4). On the morning of November 29, a chest CT showed that the infectious lesions in both lungs were significantly improved (Fig. 5), and he was discharged smoothly from the hospital that afternoon (Fig. 6). During the 2-month follow-up, his quality of life improved steadily, and returned to the pre-disease state.

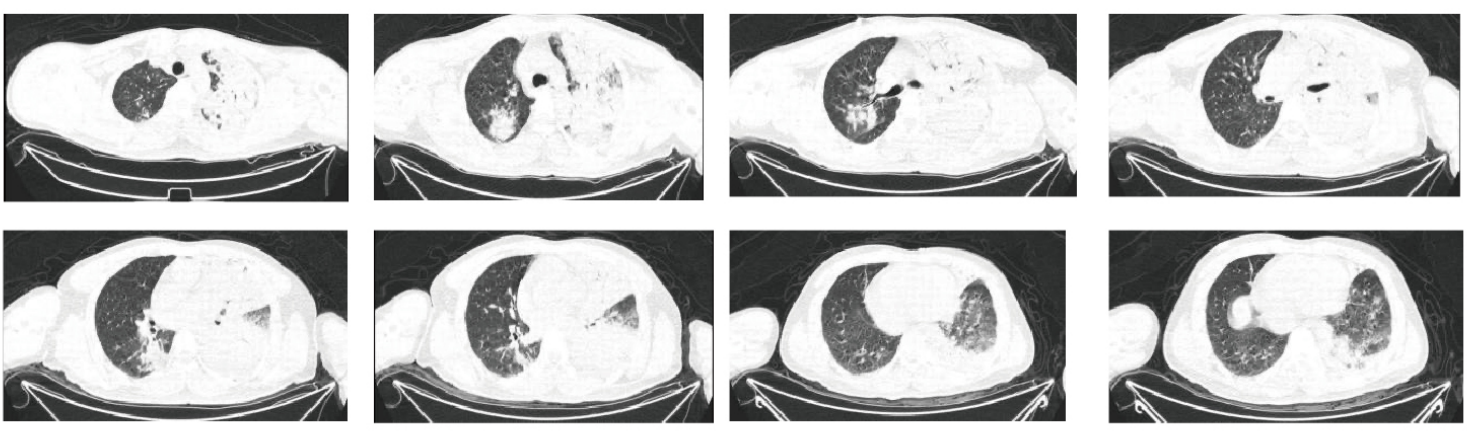

Fig. 1 CT scan of the patient (Those CT scans on the 0th day after admission).

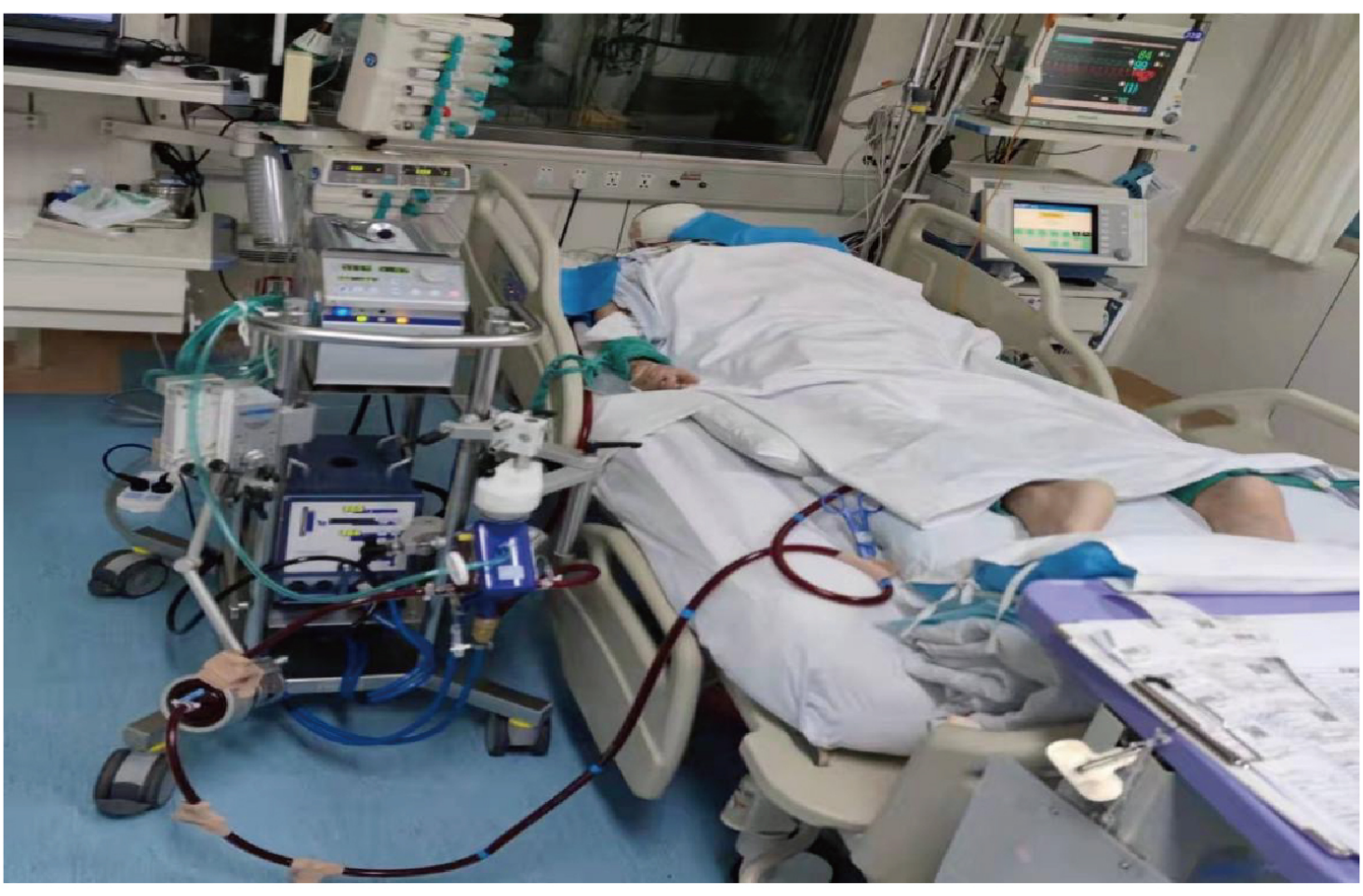

Fig. 2 VV-ECMO combined with prone position ventilation therapy.

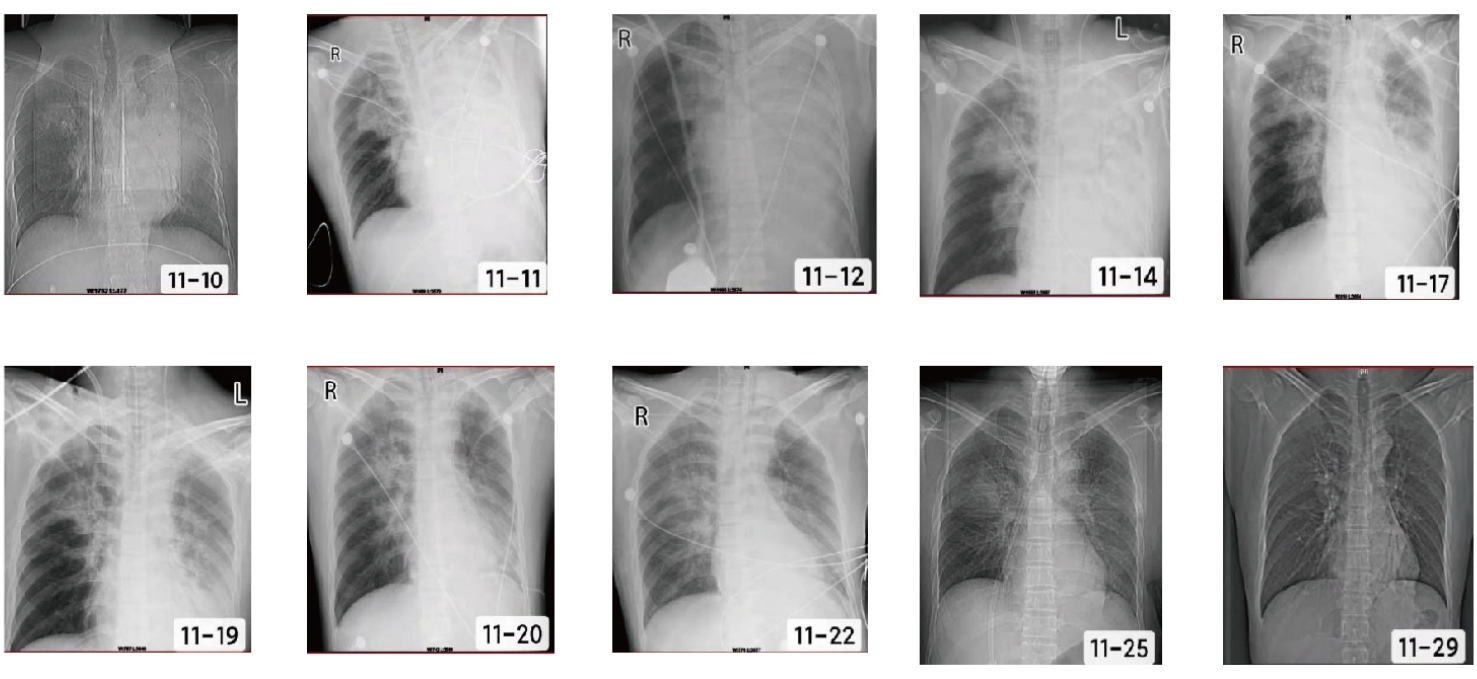

Fig. 3 X-ray of the patient

Parameters	Pre-ECMO	ECMO day1	ECMO day2	ECMO day3	ECMO day4	ECMO day5	ECMO day6	ECMO day7	ECMO day8	ECMO day9	ECMO weaning
SaO_2（%）	85	100	100	100	100	100	100	100	100	100	100
HR（p/min）	140	128	121	122	110	98	90	88	90	92	90
MAP（mmHg）	62	71	82	84	93	96	95	90	92	88	94
Hb（g/L）	101	99	77	93	96	91	90	85	96	92	94
Plt（×109/L）	42	34	35	45	43	43	31	30	41	48	81
PCT（ng/mL）	100	95.4	62.2	39.7	15.1	6.8	3.6	1.9	1.3	0.8	0.7
PaO_2（mmHg）	62	159	140	135	158	148	156	164	147	108	156
P/F（mmHg）	62	265	233	225	240	247	312	328	294	216	390
$PaCO_2$（mmHg）	47	34	38	37	35	40	35	35	41	47	39
PH	7.26	7.44	7.39	7.43	7.5	7.42	7.47	7.45	7.43	7.39	7.44
RR（/min）	25	15	15	15	15	15	15	15	15	15	15
FiO_2（%）	100	60	60	60	60	60	50	50	50	50	40

Vt（ml/kg）	6	6	6	6	6	6	6	6	6	6	6
PEEP（cmH_2O）	15	10	8	6	6	6	5	5	5	5	5
ECMO blood flow（L/min）	NA	4.6	4.2	4.4	4.2	4.2	4.2	4.0	3.8	2.4	NA
ECMO oxygen flow（L/min）	NA	3	2.5	3	3	3	3	3	2	0	NA
ECMO oxygen-concentratio（%）	NA	100 %	100 %	100 %	100 %	100 %	100 %	80%	60%	0%	NA
ECMO rev（p/min）	NA	3500	3425	3425	3425	3440	3440	3440	3440	2200	NA
Bivalirudin (mg/kg·h)	NA	0.5	0.4	0.3	0.3	0.2	0.1	0.1	0.1	0.1	NA
ACT（s）	NA	192	200	185	220	200	186	238	210	200	NA
APTT（s）	30.2	69	58	41	45	40	42	47	52	55	45
PPV（h）	NA	15h	14h	12h	16h	14h	12h	16h	14h	12h	14h

SaO2:arterial oxygen saturation；HR:heart rate；MAP:mean arterial pressure；Hb: hemoglobin；Plt：platelet；PCT：procalcitonin；PaO2:arterial partial pressure of oxygen；P/F：PaO2/FiO2；PaCO2:arterial partial pressure of carbon dioxide；PH:arterial blood pH；RR:respiratory rate；FIO2:fraction of inspired oxygen;Vt:tidal volume；PEEP:positive end-breathing pressure；ACT：activated clottingtime of WholeBlood；APTT：activated prothrombin time；PPV：prone position ventilation；NA:no application；

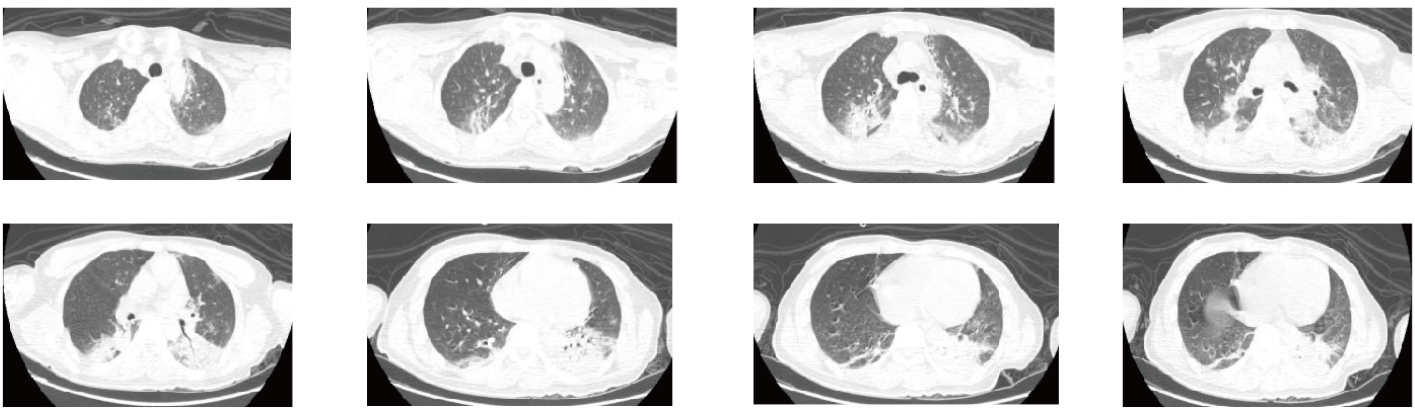

Fig. 4 CT scan of the patient (Those CT scans on the 15th day after admission).

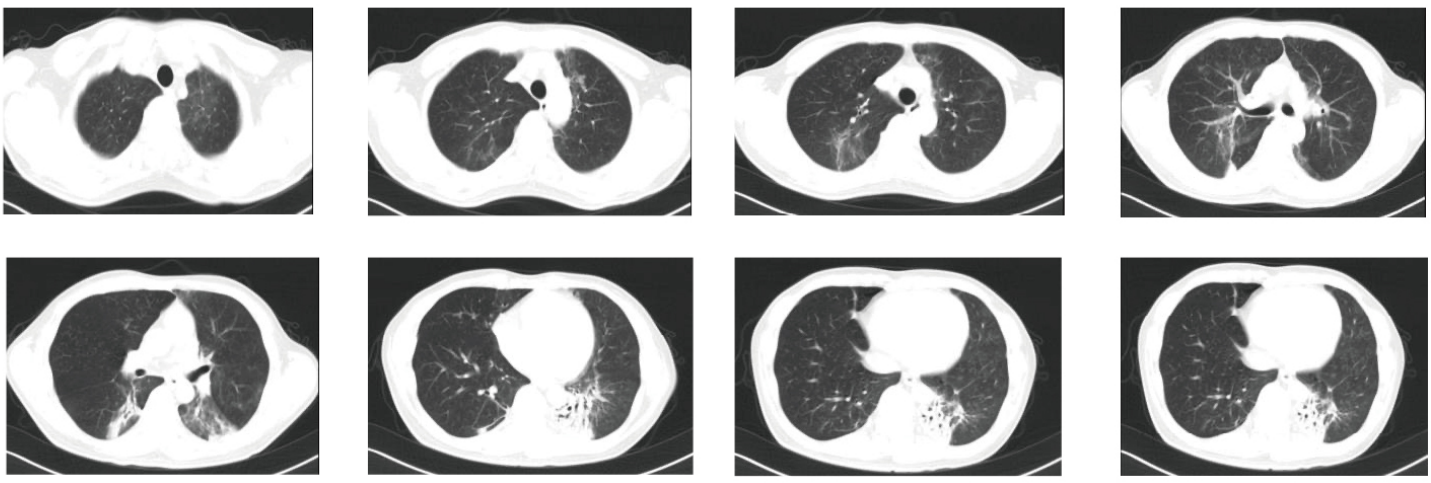

Fig. 5 CT scan of the patient (Those CT scans on the th day after admission).

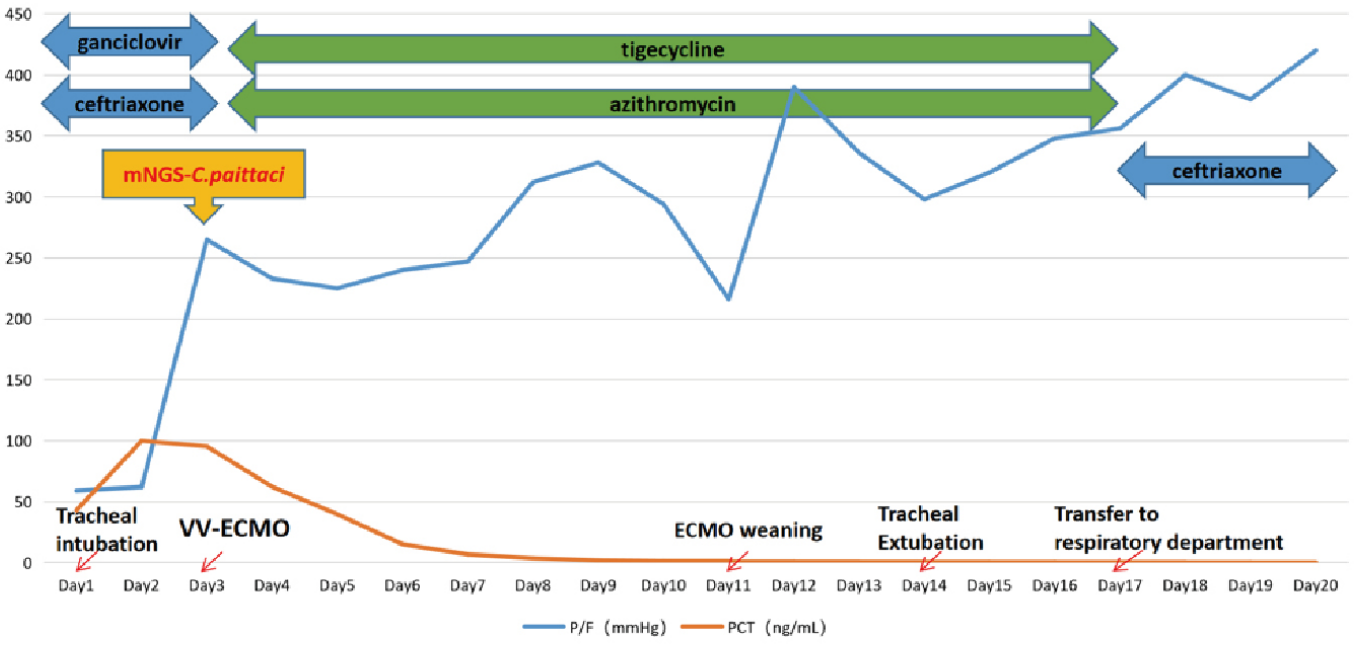

Fig. 6 Patient’s P/F, PCT and antimicrobial treatment during hospitalization Ceftriaxone 2.0g qd combined with ganciclovir 0.25g q12h(days 1-3), azithromycin 0.5g qd combined with tigecycline 50mg q12h(days 3-17), ceftriaxone 2.0g qd(days 17-20)

DISCUSSION AND CONCLUSIONS

Chlamydia psittaci pneumonia is an inflammatory pulmonary disease caused by inhalation of chlamydia Psittaci through the airway. Humans may be infected by inhaling the dust from the feathers or feces of infected birds or by inhaling aerosols from respiratory secretions, which may lead to exposure of the outer membrane proteins in the epithelial cells of respiratory mucosa, which may promote the immune response of the host and cause the overreaction of the autoimmune system, and induce pneumonia. Chlamydia psittaci can also enter cells through endocytosis, where it multiplies and causes cells to break down. Those cells rupture releases more chlamydia Psittaci protoplasmic particles, and more cells become infected. Not only do infected people get pneumonia, but they also show symptoms of systemic damage[13,14,15]. Severe psittacosis pneumonia can be life-threatening. There may be no obvious symptoms in the early stage, but with the development of the disease, respiratory failure, ARDS, mixed infection in the lungs, bacterial migration into the blood, resulting in bacteremia and septic shock, may be accompanied by varying degrees of cognitive impairment, liver and kidney failure, abnormal blood system, and even multi-organ failure[16]. But due to a lack of specific history of epidemiology, clinical manifestation, and imaging features, the diagnosis of this disease is very difficult. Its and by viruses, fungi, and certain bacteria such as (legionella) caused by CAP have many common characteristics, can be characterized by headache, high fever, cough, and psychiatric disorders[2,17]. If not a timely diagnosis and correctly treat, it can lead to death.

With the widespread application of MNGS in recent years, the detection rate of chlamydia Psittaci has been improved, which enables timely and effective targeted treatment ［18］. As a new molecular biological detection method, MNGS has the advantage of a wide detection range and no need to specify suspected pathogenic microorganisms in advance, Which can be used to diagnose meningitis, encephalitis, and lower respiratory tract infections. In our hospital, MNGS results are available within 24-48 hours, but conventional sputum cultures take 5-7 days and many cultures are negative. MNGS 'ability to obtain the accurate and timely diagnosis of infectious microorganisms is a key advantage. When treating patients with severe pneumonia, ICU physicians need to identify the causative agent early and make an accurate diagnosis to provide targeted treatment. Psittacosis is often misdiagnosed because of its difficult diagnosis and atypical clinical features. In this case study, the patient had symptoms of pneumonia and encephalitis. On the first day of admission, alveolus irrigation fluid was taken for culture, and CSF was taken for mNGS on the second day. As a result, the mNGS test report was obtained on the third day, indicating chlamydia Pnautilus, while the sputum culture result was negative on the sixth day. Compared with traditional sputum culture, the application of MNGS in atypical pathogen infection can shorten the diagnosis time to the maximum extent and strive for the treatment opportunity for severe patients.

At present, tetracycline antibiotics are the preferred drug for the treatment of chlamydia Psittaci [2], and the course of treatment lasts at least 3 weeks to avoid recurrence. Macrolides can be used as a good alternative when tetracycline therapy alone is not effective. Severe patients may be treated with tetracycline combined with macrolides or quinolones, while patients with hemodynamic instability and respiratory failure may also require circulatory and respiratory support[19]. In this case study, the patient presented symptoms of pneumonia and encephalitis at admission, and pneumonia progressed rapidly, resulting in respiratory failure, refractory hypoxemia, and sepsis. We experienced the combination of ceftriaxone 2 g qd with ganciclovir 0.25 g q12h to anti-infection treatment, but further aggravating had instead not improved. At stake, we need to determine the primary infection bacteria targeted treatment as soon as possible. In addition to collecting sputum cultivation, alveolar lavage fluid cultivation, respiratory virus antibody, such as conventional detection means, did a lumbar puncture on the day after admission, CSF was collected for mNGS. While awaiting the results, the patient's respiratory failure worsened and hemodynamics became unstable, requiring further respiratory and circulatory support to keep vital signs stable. Although circulation was maintained with norepinephrine support, hypoxia persisted (P/F $<$ 80mmHg), ventilator support conditions were high, and MODS continued to worsen. VV-ECMO was used to provide a gas exchange on the third day of admission. Adequate oxygen supply is essential for the recovery of organ function in patients with MODS. VV-ECMO can provide O2 at 3mL /(kg·min) and remove CO2 at 3-6ml/(kg·min), fully meeting the metabolic needs of the body[20]. With the support of VV-ECMO, the protective lung ventilation strategy was adopted to rest the lung and gain an opportunity for the treatment of the primary disease. After VV-ECMO support, MNGS results returned: Chlamydia psittacis, so the antibiotics were adjusted to azithromycin 0.5g QD combined with tigecycline 50mg q12h. The correct application of antibiotics allowed the infection to be controlled quickly. Without the MNGS, the disease may be delayed, unnecessary treatment may be required, and even death may result.

Many studies have validated the therapeutic strategy of VV-ECMO combined with PPV[21,22,23]. These results suggest that VV-ECMO combined with PPV can further improve oxygenation and promote recovery of the primary disease without significant complications, and more importantly, this combination therapy is associated with a higher chance of withdrawal and survival. A physiological study conducted by Franchineau et al. [24] also confirmed that this combination therapy was beneficial to improving pulmonary mechanics and reducing ventilator-associated lung injury (VILI). The mechanisms of PPV include a. Correction of refractory hypoxemia: reduce intrapulmonary shunt, improve pulmonary ventilation and blood flow ratio, increase functional residual volume. In addition, postural drainage also contributes to improved oxygenation. b. Improve hypercapnia: reduce alveolar dead space in the ventral region. c. It is helpful for the implementation of lung-protective strategies: in a prone position, the distribution of gravity pressure gradient in the pleural cavity is more uniform, which promotes alveolar reexpansion in the dorsal region, reduces the compliance of chest wall in the ventral region, reduces alveolar overexpansion, and improves the homogeneity of lung ventilation. The results of a study[25] demonstrate that in patients with severe ARDS, a protective ventilation strategy with a PPV duration of at least 12h can significantly reduce mortality. In this case study, we chose the principle of "prone position priority", at least PPV 12h per day, and the longer the better if the patient can tolerate it. In this process, medical care focuses on ECMO intubation and puncture point, while firmly fixing endotracheal intubation, fine nursing to avoid pressure ulcers, skin ulceration, pipeline shedding, and other complications, as long as adequate preparation, ECMO combined with PPV is safe and effective.

CONCLUSION

In conclusion, mNGS is particularly important for the diagnosis of severe atypical pneumonia and guides the application of antibacterial drugs. And Chlamydia psittaci infaction is not only difficult to diagnose and easily misdiagnose, but also lead to life-threatening severe ARDS. Therefore, when the diagnosis is confirmed and the conventional treatments are ineffective, VV-ECMO support should be performed as soon as possible to gain more treatment time for primary lung lesions.

Declarations

Competing interests

The authors declare that they have no competing interests.

Acknowledgements

The authors thank this patient and his familie for agreeing to use their data for research purposes, and specifically, for publication of this report.

Ethics approval and consent to participate

As a case report, our paper did not require any referral to our institutional clinical ethics committee.

Consent to publication

Written informed consent was obtained from the patient for publication of this report and any accompanying images.

Availability of data and materials

All the data supporting our findings is contained within the manuscript. The datasets used and/or analysed during the current study are available from the corresponding author on reasonable request.

Authors' contributions

YWT and JLT contributed equally to this work. YWZ, YWT, AMGL, and JG participated in manuscript drafting. YQW, YWT, HL and ZKW collected and analyzed clinical data. YL and LYS participated in data interpretation and manuscript revision. All authors read and approved the final manuscript.

References

1. de Gier B, Hogerwerf L, Dijkstra F, van der Hoek W. Disease burden of psittacosis in the Netherlands. Epidemiol Infect. 2018;146(3):303-305.
2. Balsamo G, Maxted AM, Midla JW, et al. Compendium of Measures to Control Chlamydia psittaci Infection Among Humans (Psittacosis) and Pet Birds (Avian Chlamydiosis), 2017. J Avian Med Surg. 2017;31(3):262-282.
3. Zhang H, Zhan D, Chen D, et al. Next-generation sequencing diagnosis of severe pneumonia from fulminant psittacosis with multiple organ failure: a case report and literature review. Ann Transl Med. 2020;8(6):401.
4. Hogerwerf L, DE Gier B, Baan B, VAN DER Hoek W. Chlamydia psittaci (psittacosis) as a cause of community-acquired pneumonia: a systematic review and meta-analysis. Epidemiol Infect. 2017;145(15):3096-3105.
5. Vande Weygaerde Y, Versteele C, Thijs E, et al. An unusual presentation of a case of human psittacosis. Respir Med Case Rep. 2018;23:138-142. Published 2018 Feb 2.
6. Ravichandran K, Anbazhagan S, Karthik K, Angappan M, Dhayananth B. A comprehensive review on avian chlamydiosis: a neglected zoonotic disease. Trop Anim Health Prod. 2021;53(4):414. Published 2021 Jul 27.
7. Mair-Jenkins J, Lamming T, Dziadosz A, et al. A Psittacosis Outbreak among English Office Workers with Little or No Contact with Birds, August 2015. PLoS Curr. 2018;10:ecurrents.outbreaks.b646c3bb2b4f0e3397183f31823bbca6. Published 2018 Apr 27.
8. Shi Y, Chen J, Shi X, et al. A case of chlamydia psittaci caused severe pneumonia and meningitis diagnosed by metagenome next-generation sequencing and clinical analysis: a case report and literature review. BMC Infect Dis. 2021;21(1):621. Published 2021 Jun 30.
9. Brodie D, Vincent JL, Brochard LJ, et al. Research in Extracorporeal Life Support: A Call to Action. Chest. 2018;153(4):788-791.
10. Karagiannidis C, Brodie D, Strassmann S, et al. Extracorporeal membrane oxygenation: evolving epidemiology and mortality. Intensive Care Med. 2016;42(5):889-896.
11. Extracorporeal Life Support Organization. ELSO Registry report [R/OL]. （2021）[2021-12-16].https://www.elso.org/Registry/Statistics/InternationalSummary.aspx.
12. Combes A, Hajage D, Capellier G, et al. Extracorporeal Membrane Oxygenation for Severe Acute Respiratory Distress Syndrome. N Engl J Med. 2018;378(21):1965-1975.
13. Knittler MR, Sachse K. Chlamydia psittaci: update on an underestimated zoonotic agent. Pathog Dis. 2015;73(1):1-15.
14. Stokes HS, Berg ML, Bennett ATD. A Review of Chlamydial Infections in Wild Birds. Pathogens. 2021;10(8):948. Published 2021 Jul 28.
15. Su S, Su X, Zhou L, et al. Severe Chlamydia psittaci pneumonia: clinical characteristics and risk factors. Ann Palliat Med. 2021;10(7):8051-8060.
16. Wichert A, Lukasewitz P, Häuser MH, Bittersohl J, Lennartz H. ARDS in fulminant ornithosis and treatment with extracorporeal lung assist. Int J Artif Organs. 2000;23(6):371-374.
17. Gacouin A, Revest M, Letheulle J, et al. Distinctive features between community-acquired pneumonia (CAP) due to Chlamydophila psittaci and CAP due to Legionella pneumophila admitted to the intensive care unit (ICU). Eur J Clin Microbiol Infect Dis. 2012;31(10):2713-2718.
18. Chen X, Cao K, Wei Y, et al. Metagenomic next-generation sequencing in the diagnosis of severe pneumonias caused by Chlamydia psittaci. Infection. 2020;48(4):535-542.
19. Wang L, Shi Z, Chen W, Du X, Zhan L. Extracorporeal Membrane Oxygenation in Severe Acute Respiratory Distress Syndrome Caused by Chlamydia psittaci: A Case Report and Review of the Literature. Front Med (Lausanne). 2021;8:731047. Published 2021 Oct 15.
20. Lango R, Szkulmowski Z, Maciejewski D, Sosnowski A, Kusza K. Revised protocol of extracorporeal membrane oxygenation (ECMO) therapy in severe ARDS. Recommendations of the Veno-venous ECMO Expert Panel appointed in February 2016 by the national consultant on anesthesiology and intensive care. Anaesthesiol Intensive Ther. 2017;49(2):88-99.
21. Guervilly C, Prud'homme E, Pauly V, et al. Prone positioning and extracorporeal membrane oxygenation for severe acute respiratory distress syndrome: time for a randomized trial?. Intensive Care Med. 2019;45(7):1040-1042.
22. Chaplin H, McGuinness S, Parke R. A single-centre study of safety and efficacy of prone positioning for critically ill patients on veno-venous extracorporeal membrane oxygenation. Aust Crit Care. 2021;34(5):446-451.
23. Giani M, Martucci G, Madotto F, et al. Prone Positioning during Venovenous Extracorporeal Membrane Oxygenation in Acute Respiratory Distress Syndrome. A Multicenter Cohort Study and Propensity-matched Analysis. Ann Am Thorac Soc. 2021;18(3):495-501.
24. Franchineau G, Bréchot N, Hekimian G, et al. Prone positioning monitored by electrical impedance tomography in patients with severe acute respiratory distress syndrome on veno-venous ECMO. Ann Intensive Care. 2020;10(1):12. Published 2020 Feb 3.
25. Munshi L, Del Sorbo L, Adhikari NKJ, et al. Prone Position for Acute Respiratory Distress Syndrome. A Systematic Review and Meta-Analysis. Ann Am Thorac Soc. 2017;14(Supplement_4):S280-S288.

第6届中国医师协会体外生命支持年会
The 6th Chinese Society of ExtraCorporeal Life Support Annual Meeting

Successful treatment of near-fatal asthma with ECMO: A case report and literature review

Short title: Successful treatment of near-fatal asthma with ECMO

Summary

Near-fatal asthma (NFA) can lead to severe hypercapnia and even sudden cardiac arrest but can be reversed by extracorporeal membrane oxygenation (ECMO). We report the case of a 37-year-old man diagnosed with NFA. He was treated with fluid rehydration, spasmolysis, glucocorticoid, and mechanical ventilation, and his condition was temporarily relieved. However, his condition rapidly worsened, and he presented with progressive respiratory distress, sharp increase in airway pressure, decreased tidal volume, and barometric injury. The patient was then treated with venovenous ECMO in the prone position. Five days later, he was successfully weaned from ECMO. ECMO could be used for NFA at the right time to provide adequate gas exchange for patients in order to reduce lung damage and prevent death.

Keywords: Extracorporeal Membrane Oxygenation; Glucocorticoids; Respiration, Artificial; Hypercapnia; Respiratory Distress Syndrome; Asthma

Introduction

Near-fatal asthma (NFA) is the most serious form of asthma with an extremely high mortality1. At present, there is no unified or specific diagnostic standard for NFA. The clinical features of NFA include hypercapnia, severe acidosis, respiratory and cardiac arrest, and the need for mechanical ventilation through endotracheal intubation2. In the case of extremely severe airway obstruction, hypoxemia cannot be corrected, even with the maximal optimization of respiratory support parameters, which may lead to severe barotrauma, hemodynamic instability, and eventual death. Extracorporeal membrane oxygenation (ECMO) can be used in the treatment of NFA, because it can provide sufficient gas exchange to remove CO2 and improve oxygenation3, while also minimizing the risk of ventilator-associated lung injury by reducing inhaled oxygen concentration, airway pressure, and tidal volume to allow the lungs to rest4. This paper reports the case of a 37-year-old male patient with NFA. Despite receiving all possible treatments including mechanical ventilation, the patient's condition continued to worsen. The patient finally improved and was discharged from the hospital after ECMO treatment.

Case study

This patient was a 37-year-old male chef working in a hotel. He was transferred to our hospital from another hospital at 20:00 h on June 16, 2021 because of paroxysmal asthma with unconsciousness for 2 days. Two days before admission, the patient had a sudden asthmatic attack and was sweating at about 22:00 h after dining out and drinking wine at night. He became unconscious and was sent to the emergency room of a local hospital. When entering the emergency room, this patient had a minimum SpO2 of 35–45% and had extreme difficulty with breathing. After tracheal intubation, the patient was admitted to the intensive care unit (ICU) of the local hospital for "status asthmaticus". After admission, he underwent mechanical ventilation (pressure-controlled ventilation), analgesia and sedation, antispasmodic and antiasthmatic treatment (with terbutaline, doxofylline, and budesonide), fluid infusion, and maintenance of internal environmental stability. After treatment, the consciousness of this patient improved, but the monitored PaCO2 and airway resistance gradually increased compared with previous values, and the dyspnea was re-intensified. On June 15, the patient was started on neuromuscular blockade, endotracheal intubation, and atomization inhalation of magnesium sulfate and adrenaline, and the mechanical ventilation was changed to volume-controlled (VC) ventilation. However, the airway pressure and PaCO2 gradually increased, the lowest tidal volume was < 200 ml, and bulbar conjunctival edema occurred. From 02:00 h on June 16, blood gas measurements were performed many times, which yielded PCO2 > 110 mmHg. Further optimization of respiratory support parameters (VC 250 ml, positive end-expiratory pressure 4 cmH2O, prolonged expiratory time, and increased alarm limit of ventilator pressure), peak airway pressure up to 90 cmH2O, platform pressure up to 43 cmH2O, and tidal volume less than 100 ml were applied. Chest computed tomography (CT; Figure 1) performed on the morning of June 16 revealed superior mediastinal emphysema and subcutaneous emphysema at the left cervical root. Our ECMO team successfully finished venovenous (VV)-ECMO treatment at 17:00 h and immediately transferred the patient to the ICU of our hospital.

After his transfer to our department, the patient was treated with symptomatic and supportive treatment, such as VV-ECMO, lung protective ventilation, analgesics, sedatives, muscle relaxants and glucocorticoids, anti-infectious agents, antispasmodic and antiasthmatic treatment, prone position ventilation, blood purification, and maintenance of internal environmental stability. The relevant data trends are presented in Table 1. After ECMO placement and transfer to our hospital, respiratory oxygenation was barely maintained on full-flow ECMO, but the airway resistance was still very high. To limit the plateauing of airway pressure, the minimum tidal volume was < 20 ml/time (Figure 2 and Video 1). Tracheoscopy on June 17 showed a large number of transparent and sticky secretions in the bronchial lumens of the upper and lower lobes of both lungs, and the tracheobronchial mucosa had longitudinal folds, indicating severe tracheal and bronchial spasms. From 0:00 h on June 18, the tidal volume gradually increased. With the gradual decrease of airway resistance and improvement of ventilation, the patient's respiratory oxygenation was maintained at a satisfactory level, and PaCO2 was maintained at a normal value. After attempting to stop the use of muscle relaxants and taper off analgesics and sedatives, the patient gradually became conscious. CT re-examination on the morning of June 18 (Figure 3, Video 2) showed (1) atelectasis in the upper lobes of both lungs, stenosis, and occlusion in the proximal end of the right upper lobe bronchus, and (2) a few fibrous indurated lesions in both lungs, with bilateral pleural effusion and pulmonary atelectasis. After a series of comprehensive treatments, VV-ECMO was successfully ceased on June 21, 2021, the ventilator was successfully removed, and the patient was transferred to the respiratory department on June 23, 2021. The patient was discharged on July 5, 2021.

Discussion

In acute severe asthma, extensive airway inflammation and mucus plug formation block the airway5. Airway inflammation leads to airway hyperresponsiveness, bronchial smooth muscle contraction, mucosal edema, and increased mucus secretion; these further lead to increased airway resistance, dynamic pulmonary hyperinflation, and increased breathing work, followed by uneven ventilation, hypoxemia, and ventilation-perfusion mismatch caused by hypercapnia6.

Mechanical ventilation is an important lifesaving measure for NFA, but the mortality of asthmatic patients may be related to the mechanical ventilation itself rather than disease progression7,8. Regardless of the type of mechanical ventilation selected, it should be designed to avoid barotrauma, minimize dynamic pulmonary hyperinflation, and ensure adequate oxygenation in NFA patients. A certain degree of hypercapnia is allowed until bronchodilators and steroids can improve airway resistance9. Generally, patients with NFA tolerate moderate hypercapnia and respiratory acidosis, and the airway pressure is limited by the low respiratory rate and low tidal volume10. However, in the case of severe airway obstruction, even maximum adjustment of mechanical ventilation parameters cannot correct hypoxemia, and death from asphyxia quickly occurs due to extreme airflow restriction and hypoxia.

After the onset of asthma, the condition of this patient slightly improved following mechanical ventilation, fluid infusion, antispasmodic therapy, and antiasthmatic treatment, but his condition worsened again and progressed to a state where there was almost no ventilation within a short period of time, followed by severe barotrauma and hemodynamic instability. The doctors in the local hospital were forced to markedly raise the pressure alarm limit, but the ventilator could not even complete the most basic dead space ventilation, and the patient was likely in a state of "complete airway obstruction". From another point of view, the pressure in the breathing circuit of the patient was very high at that time; the corresponding airway resistance could not be overcome under notably strong control-mode ventilation, and the gas could not reach the distal airway and alveoli. Possibly, the airflow in the entire airway of the patient was in a state of relative rest. The subsequent tracheoscopic findings were consistent with the aforementioned gross pathological features. In this critical state, VV-ECMO is urgently used to achieve sufficient oxygen supply and CO2 clearance, allowing the lungs to rest and bronchospasm and inflammation regression to occur11.

In patients with NFA, the time required for airway resistance and compliance to return to normal greatly varies after routine treatment. It cannot be predicted when the bronchospasm will be relieved. Therefore, ECMO treatment should be considered before barotrauma and volutrauma are caused by refractory NFA, especially when severe hypoxemia is present because of a serious mismatch of ventilation/blood flow caused by increased airway resistance and restricted airflow. ECMO can be considered in patients with NFA whose mechanical ventilation parameters have been set to be equivalent to the limits, but whose conditions continue to deteriorate, accompanied by the occurrence of severe hypoxemia, acidosis, and hemodynamic instability that cannot be corrected.3 A lung-protective ventilation strategy should also be adopted after the patient is placed on ECMO to reduce ventilator-associated lung injury and oxygen poisoning; at the same time, during ECMO support, patients can be actively treated with bronchoscopic bronchial alveolar lavage to gradually improve pulmonary dynamic compliance12. Our report showed that more than 30 hours after this patient was placed on ECMO, his airway pressure gradually decreased, compliance gradually improved, and tidal volume gradually increased until he was safely evacuated from ECMO and ventilation. The condition in the early stage of the entire treatment process was notably dangerous, while it was well-reasoned that satisfactory results were achieved after ECMO was used. Of course, this depends more on the precise control of the entire treatment team regarding the details of the ECMO puncture procedure, operation management, withdrawal, and management of mechanical ventilation.

Conclusion

To some extent, the clinical process of NFA is similar to that of fulminant myocarditis. Considering that tracheal and bronchial spasms are ultimately reversible, the use of ECMO at an appropriate time should be actively considered to provide adequate gas exchange for patients, reduce lung injury, and allow the lungs to rest in order to reduce mortality.

References

1. Dhuper S, Maggiore D, Chung V, Shim C. Profile of near-fatal asthma in an inner-city hospital. Chest 2003;124:1880-1884. doi:10.1378/chest.124.5.1880
2. Rodrigo GJ, Rodrigo C, Nannini LJ. [Fatal or near-fatal asthma: clinical entity or incorrect management?]. Arch Bronconeumol 2004;40:24-33. doi:10.1016/s1579-2129(06)60188-2
3. Yeo HJ, Kim D, Jeon D, Kim YS, Rycus P, Cho WH. Extracorporeal membrane oxygenation for life-threatening asthma refractory to mechanical ventilation: analysis of the Extracorporeal Life Support Organization registry. Crit Care 2017;21:297. doi:10.1186/s13054-017-1886-8
4. Noah MA, Peek GJ, Finney SJ, et al. Referral to an extracorporeal membrane oxygenation center and mortality among patients with severe 2009 influenza A(H1N1). JAMA 2011;306:1659-1668. doi:10.1001/jama.2011.1471
5. Kaza V, Bandi V, Guntupalli KK. Acute severe asthma: recent advances. Curr Opin Pulm Med 2007;13:1-7. doi:10.1097/MCP.0b013e328011a91c
6. Carrié S, Anderson TA. Volatile anesthetics for status asthmaticus in pediatric patients: a comprehensive review and case series. Paediatr Anaesth 2015;25:460-467. doi:10.1111/pan.12577
7. Anzueto A, Frutos-Vivar F, Esteban A, et al. Incidence, risk factors and outcome of barotrauma in mechanically ventilated patients. Intensive Care Med 2004;30:612-619. doi:10.1007/s00134-004-2187-7
8. Hodder R, Lougheed MD, FitzGerald JM, Rowe BH, Kaplan AG, McIvor RA. Management of acute asthma in adults in the emergency department: assisted ventilation. CMAJ 2010;182:265-272. doi:10.1503/cmaj.080073
9. Georgopoulos D, Kondili E, Prinianakis G. How to set the ventilator in asthma. Monaldi Arch Chest Dis 2000;55:74-83.
10. Holley AD, Boots RJ. Review article: management of acute severe and near-fatal asthma. Emerg Med Australas 2009;21:259-268. doi:10.1111/j.1742-6723.2009.01195.x
11. Di Lascio G, Prifti E, Messai E, et al. Extracorporeal membrane oxygenation support for life-threatening acute severe status asthmaticus. Perfusion 2017;32:157-163. doi:10.1177/0267659116670481
12. Nussbaum E. Pediatric fiberoptic bronchoscopy: Clinical experience with 2,836 bronchoscopies. Pediatr Crit Care Med 2002;3:171-176. doi:10.1097/00130478-200204000-00015

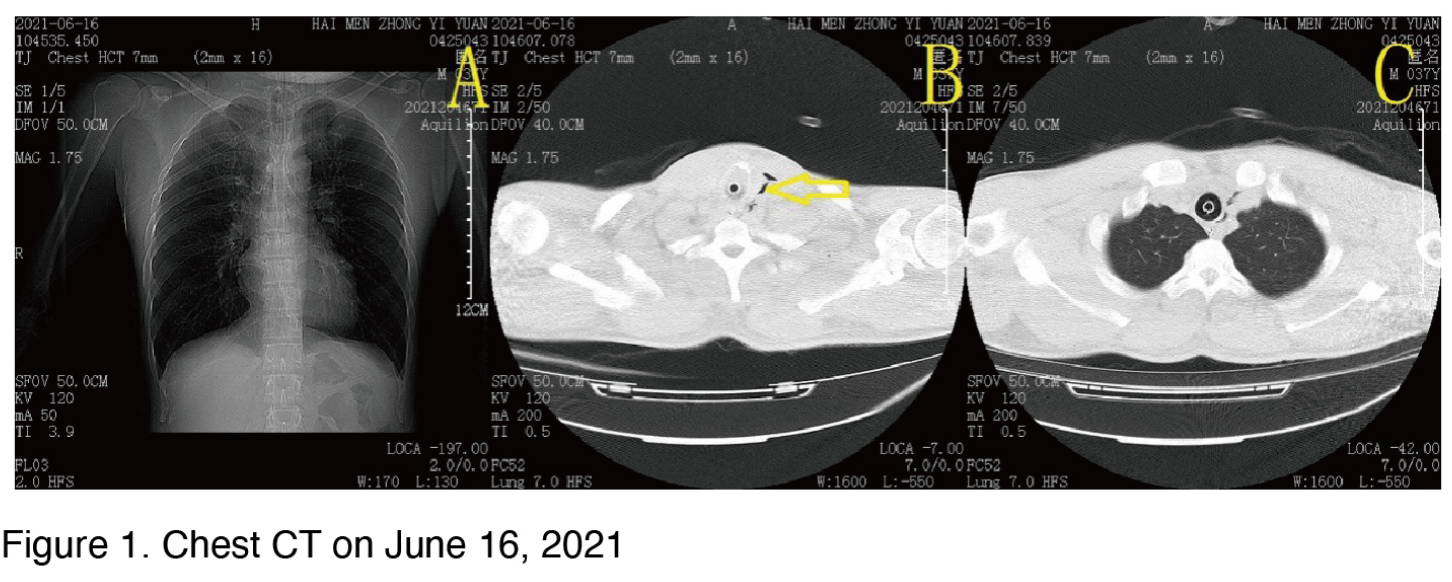

Figure 1. Chest CT on June 16, 2021

Pneumatosis and subcutaneous emphysema can be seen in the superior mediastinum

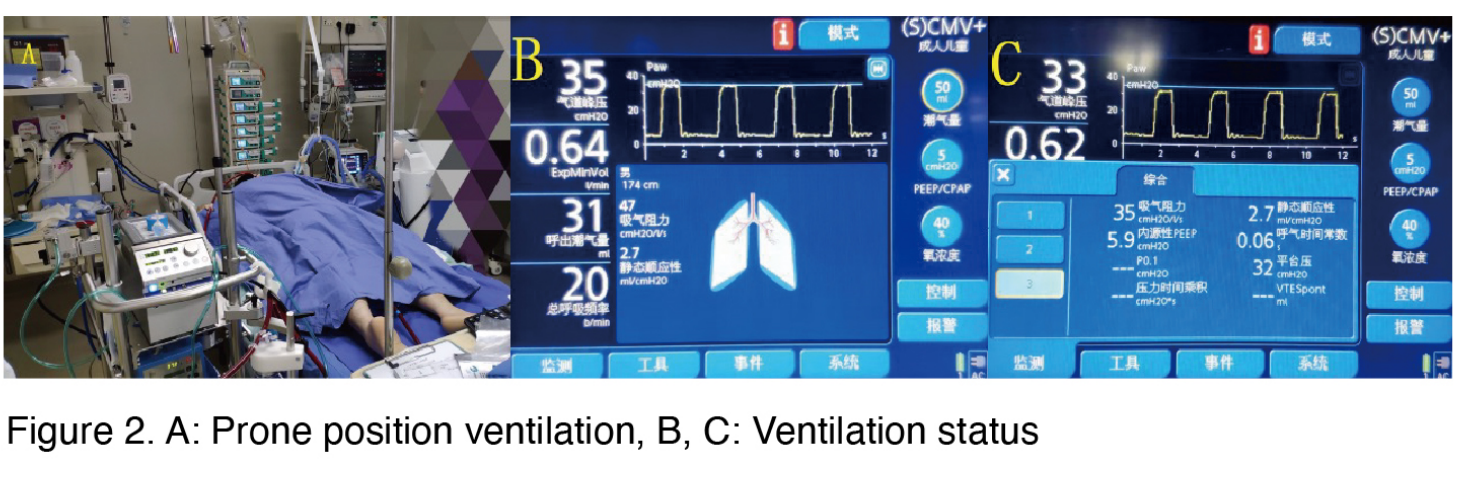

Figure 2. A: Prone position ventilation, B, C: Ventilation status

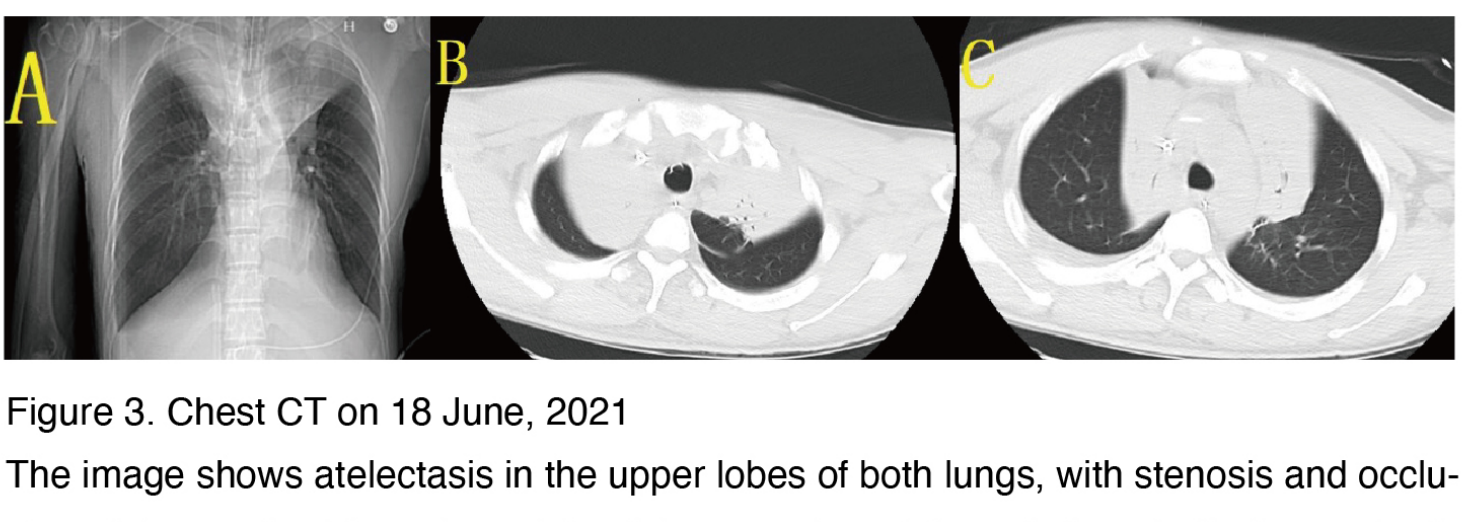

Figure 3. Chest CT on 18 June, 2021

The image shows atelectasis in the upper lobes of both lungs, with stenosis and occlusion of the proximal bronchus of the right upper lung; bilateral pleural effusion and pulmonary atelectasis

Table 1 Changes of respiratory parameters after ECMO treatment

ECMO time	2h	6h	12h	24h	36h	48h	72h	96h
VT(ml)	15	17	16	35	180	300	400	460
Pplat(cmH_2O)	25	27	26	28	30	28	18	16
PEEP(cmH_2O)	5	5	5	5	5	6	6	6
FiO_2(V)%	40	40	40	40	40	40	40	40
FiO_2(E)%	100	100	100	100	100	100	80	50
ECMO(rad)	4750	4750	4750	4750	4200	3900	3500	3500
ECMO(L/min)	5.2	5.2	5.07	5.1	4.52	4.16	4	3.8
PH	7.405	7.295	7.302	7.315	7.328	7.316	7.345	7.5
PaCO_2(mmHg)	43.7	67	63	56	40.7	44.4	34.8	35.6
PaO_2(mmHg)	45	64.3	67	69	71.6	82.8	84.3	90
SpO_2(%)	92	95	93	95	95	99	99	99

Extracorporeal Membrane Oxygenation Using a Modified Cardiopulmonary Bypass System

Xuan Song, MD, PhD1,2, Hao Wang,MD2, Kianoush B. Kashani3,4, Chunting Wang, MD, PhD1*

1Intensive Care Unit, Shandong Provincial Hospital Affiliated to Shandong First Medical University, Shandong, China
2Intensive Care Unit, Dong E Hospital, Shandong, China
3Division of Pulmonary and Critical Care Medicine, Department of Medicine, Mayo Clinic, Rochester, MN, USA
4Division of Nephrology and Hypertension, Department of Medicine, Mayo Clinic,Rochester, MN, USA

Correspondence to address: Chunting Wang, MD, PhD, Department of Intensive Care Unit, Shandong Provincial Hospital Affiliated to Shandong First Medical University, 9677 Jingshi Road, Jinan 250014, Shandong Province, China. Email: wcteicu@126.com

Extracorporeal membrane oxygenation (ECMO) provides continuous extracorporeal respiration and circulation for patients with severe cardiopulmonary failure. However, access to ECMO machines is limited, even in highly populated areas, and many hospitals do not have any ECMO access.[1] According to data of the Chinese Society of Extracorporeal Life Support (ELS) committee, in 2018, ECMO was used to treat approximately 4,000 patients in the ELS centers of 260 hospitals in China.[2]

During the COVID-19 pandemic, ECMO is often used as a last resort "lifesaver", the market demand for ECMO equipment increased sharply, but its market supply has remained limited. As a result, many patients have not been able to receive the best possible care. Here, we describe a case from April 2021 in which a cardiopulmonary bypass system was successfully used instead of a combination of ECMO and continuous renal replacement therapy (CRRT) to treat a patient who experienced refractory cardiogenic shock after coronary artery bypass grafting (CABG) at our hospital.

A 67-year-old male had undergone CABG due to three-vessel coronary artery disease and severe stenosis. Immediately after surgery, the patient exhibited hemodynamic instability. His blood pressure dropped to 68/30 mmHg and he had severely low cardiac output (CO) of 1.2 L/min, with an ejection fraction (EF) of 21%, high doses of vasopressors and Intra-Aortic Balloon Pump (IABP) were still difficult to maintain blood pressure, ECMO was urgently needed to reverse cardiogenic shock. However, the only ECMO machine in our hospital was in use, and the urgency of the patient's condition, did not allow for the transfer of ECMO equipment from outside the hospital. After discussion among the ECMO team, the decision was made to convert the cardiopulmonary bypass system (CBS) of the operating room into an ECMO alternative. The centrifugal pump head of the CBS was used to drive the blood flow, similar to the centrifugal pump on an ECMO, using a HILITE 7000 LT oxygenator (Medos, Stolberg, Germany) as the membrane oxygenator. Thus, an ECMO machine alternative was assembled in a short time.

After the establishment of the modified CBS, the hemodynamics of the patients improved rapidly and the respiration and circulation stabilized. However, the patient had severe systemic edema. In order to treat the edema, we used the roller pump of the CBS to connect a hemoconcentrator downstream of the membrane oxygenator for dehydration treatment (slow continuous ultrafiltration, SCUF). After dehydration, the blood was returned to the front of the membrane oxygenator (Figure 1). In order to control the extent of dehydration, we attached an infusion pump to the hemoconcentrator and control the speed of the dehydration by regulating the pump speed. On the second day, the patient's serum creatinine increased to 232 μmol/L, indicating acute renal injury. Continuous renal replacement therapy (CRRT) was needed, but we did not have any more available CRRT equipment. Instead, we connected a hemofilter to the cardiopulmonary bypass system roller pumps, downstream of the membrane oxygenator and the hemoconcentrator (Figure 1). The pump speed and flow was controlled using the cardiopulmonary bypass system control panel. The blood passed through the CRRT filter and the filtered blood and replacement fluid were infused back in front of the membrane oxygenator. With the combined ECMO and CRRT provided by the modified cardiopulmonary bypass system, the patient's circulation gradually stabilized and the machine was removed successfully on the sixth day after operation.

We describe the successful use of a modified cardiopulmonary bypass system to provide prolonged ECMO and CRRT. As most hospital operating rooms are equipped with CBS, that could be used to widely increase access to ECMO treatment. Particularly during a shortage of ECMO machines, CRRT, and other equipment due to a pandemic situation, CBS can replace the heart, lung, and kidney functions of patients and provide the opportunity to save lives.

In addition to increasing access, our strategy integrates the functions of ECMO, CRRT, and SCUF, reducing the complexity of pipeline connections and the chance of nosocomial infection. ECMO draws blood from a large vein and passes it through an oxygenator, where a membrane allows for exchange of oxygen and carbon dioxide.[3] The oxygenated blood is returned to an artery, effectively circulating the blood without relying on cardiac function, replacing both the heart and lungs. CBS use similar pumps to provide the same function during surgery, but also include additional pumps that can be used to connect other treatments in series with the oxygenator. Combining these functions potentially limiting the risk of infection and complications while allowing for the combination of treatments required for critically ill patients to recover.

Cardiopulmonary bypass system may successfully be used to provide ECMO and other life support to patients in the absence of available standard technology. Further studies are needed to compare the safety and efficacy of existing ECMO to modified cardiopulmonary bypass system.

Declarations

Ethics approval and consent to participate: The authors certify that they have obtained all appropriate consent forms from the guardians.

Consent for publication: Not applicable

Availability of data and materials: Not applicable

Competing interests: The authors that they do not have any competing interests.

Funding: No funding

Authors' contributions: CW contributed to the conception, XS and HW contributed to the design, XS and HW contributed to the drafting of the article, CW and KK contributed to the critical revision of the article for important intellectual content, and CW conducted the final approval of the article. The authors read and approved the final manuscript.

Acknowledgements: Not applicable

REFERENCES

1. Wallace DJ, Angus DC, Seymour CW, Yealy DM, Carr BG, Kurland K, et al. Geographic access to high capability severe acute respiratory failure centers in the United States. PloS one 2014;9:e94057.
2. Li CL, Hou XT, Hei FL, et al. [China statistics of extracorporeal life support in 2018]. Zhonghua yi xue za zhi 2019;99(24):1911-1915. (In chi). DOI: 10.3760/cma.j.issn.0376-2491.2019.24.014.
3. Cavarocchi NC. Introduction to Extracorporeal Membrane Oxygenation. Critical care clinics 2017;33(4):763-766. (In eng). DOI: 10.1016/j.ccc.2017.06.001.

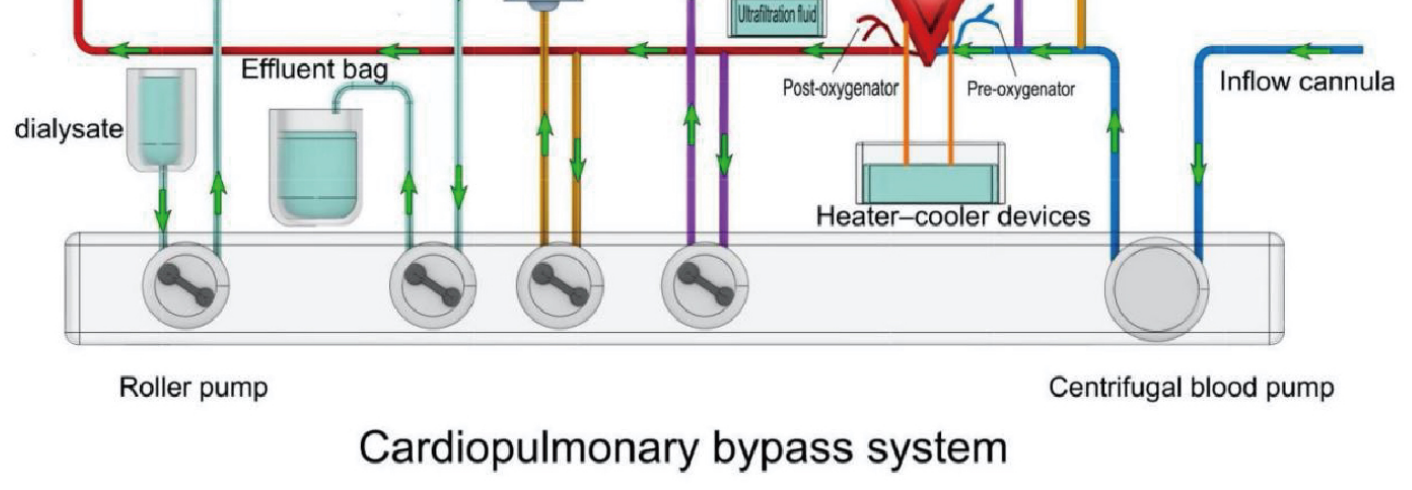

Figure 1. Schematic for the modified cardiopulmonary bypass system with ECMO, CRRT, and SCUF functions

Venovenous extracorporeal membrane oxygenation during pregnancy: a case of severe pneumonia complicated with severe acute respiratory distress syndrome

Lei Juncai1,Zhang Zhe1
1Department of Cardiac Surgery, Peking University Third Hospital, Beijing 100191, China
Corresponding author:Zhang Zhe,E-mail:zhangzhe@bjmu.edu.cn

Abstract

Severe pneumonia complicated with acute respiratory distress syndrome (ARDS) during pregnancy usually has adverse maternal and fetal outcomes, and its diagnosis and treatment are challenging. Patients are usually complicated with severe infection, and the disease progresses rapidly and is unpredictable, coupled with the uncertainty of the impact of drugs on the fetus, clinical decision-making becomes very difficult. We share a case of successful application of venovenous extracorporeal membrane oxygenation (VV-ECMO) in the treatment of a 27+2 weeks pregnant woman with severe pneumonia complicated with ARDS and successful delivery. After admission, the disease progressed rapidly, no pathogen was found in several times bacterial cultures, and the patient's condition deteriorated sharply. Emergent cesarean section was performed at the bedside in the intensive care unit to deliver a viable infant with VV-ECMO. When the conventional supportive treatment of pregnancy complicated with severe pneumonia complicated with ARDS is ineffective, timely application of ECMO and multi-disciplinary cooperation are of great significance to improve hypoxemia and strive for the opportunity of treatment.

Introduction

Pregnancy complicated with pneumonia are relatively rare. Due to the specific pathophysiological changes in pregnancy, it is very likely to develop severe pneumonia and acute respiratory distress syndrome（ARDS）1. ARDS in pregnancy is associated with high maternal and fetal mortality rates2.

As a form of advanced life support, extracorporeal membrane oxygenation（ECMO）can be used to treat patients with cardiopulmonary failure who fail to conventional life support therapy, such as mechanical ventilation, positive inotropic drugs, vasoactive drugs and so on3. While partially or completely replacing the lung function and significantly improving the patient's oxygenation and ventilation, it can make the lung rest and win enough time for the treatment to the primary disease and lung recovery3. It has become an ultimate effective treatment for severe respiratory failure.

Given the potential risk of bleeding and thromboembolism in the application of ECMO, data on the use of ECMO in the treatment of pregnant women is still very scarce, mainly limited to case reports. Despite these risks and challenges, reported data indicates the maternal and fetal survival rates with ECMO during pregnancy are significantly higher than those in the general adult population, ranging from 70% to 80% and 70% respectively4-7. In comparison, 2020 annual report issued by Extracorpreal Life Support Organization(ELSO) indicates the survival rate of adults receiving Venovenous-ECMO(VV-ECMO) treatment was 59% and only 44% for Venoarterial-ECMO(-VA-ECMO)8. We present a clinical experience of using ECMO to successfully rescue a second-trimester parturient with severe pneumonia secondary to bacterial infection complicated with severe ARDS, and successfully deliver a viable baby with the assistance of ECMO.

Case presentation

A 31-year-old parturient women had regular menstruation and regular antenatal examination. Gestational diabetes was diagnosed by Oral Glucose Tolerance Test (OGTT) test at 25 weeks of gestation, and diet and exercise guidance were given. She was admitted to hospital at 27+2 week of pregnancy with a 3-day history of fever and dyspnea. The patient had no obvious cause of fever 3 days before admission, and the highest body temperature was 39.6 degrees Celsius, accompanied by stuffy nose, runny nose and cough, so she went to the febrile emergency department. The blood routine examination showed that white blood cell was 5.64×10^9/L, the percentage of neutrophils was 88%, absolute value of neutrophils was 4.96×10^9/L, platelet count was 164×10^9/L, C-reaction protein(CRP) was 13.1 mg/L, Procalcitonin(PCT) was 0.07 ng/mL. COVID-19 and influenza A/B virus screening were all negative.Considering the possibility of upper respiratory tract infection. Physical hypothermia and oral antipyretic drugs were given, and then the body temperature decreased gradually. One day before admission, she began to have mild dyspnea, mild lip cyanosis, 24 hours later, dyspnea worsened at night, so she went to the obstetric emergency department to check the peripheral blood oxygen saturation 77%, respiratory rate 51 breaths per minute, heart rate 134 beats per minute(bpm), blood pressure 123/79mmHg, blood gas analysis showed PH 7.29,PaO2 37mmHg,PaCO2 34.1mmHg,Lactate 12mmol/L. Blood routine examination showed that leukocytes 3.53×10^9/L, platelet 138×10^9/L, neutrophils percentage 91.3%, CRP 210.8 mg/L, PCT 85.74 ng/mL, Chest computed tomography(CT) showed diffuse bilateral lung infiltration, especially in the left lung, with a small amount of effusion in pericardium and left pleural cavity（Fig.1 and Fig.2）, these were consistent with pneumonia. Severe pneumonia (unknown pathogen), ARDS ,type I respiratory failure and metabolic acidosis were diagnosed. She was given mask oxygen inhalation, yet peripheral blood oxygen saturation still did not improve.

Physical examination indicated that the height of the uterus was 26 centimetre, the abdominal circumference was 86cm, the fetal heart rate was 135 bpm, the general condition was poor, the lips and nail bed were obviously cyanotic, and complicated with triple concave sign and shortness of breath.

Due to progressing respiratory dysfunction,she was transferred to Intensive Care Unit(ICU) for tracheal intubation and mechanical ventilation. Given the unknown pathogen, Vancomycin, Tylenol, Azithromycin and Liwei were given to fight infection,and methylprednisolone was intravenously dripped to alleviate the poisoning symptoms of the patient. Even though the patient was intubated, the blood oxygen saturation still fluctuated at 83-90%, the pulse rate was 124bpm, the respiratory rate was 26 times per minute, the blood pressure was 100/63mmHg, the oxygenation index PaO2/FiO2 was less than 80mmHg, and oxygenation was difficult to maintain, but the bedside echocardiography showed that there was no obvious abnormality in ventricular function and Left ventricle eject fraction(LVEF) was 66%, which can basically exclude the dyspnea caused by cardiac insufficiency.

The patient's respiratory failure developed rapidly within a few hours.Although ECMO may lead to bleeding, thromboembolism, infection, renal failure and other complications, Our multidisciplinary experts team agreed that timely use of ECMO could significantly improve maternal and fetal oxygenation and prolong the fetus to 28 weeks into perinatal period as far as possible in order to ensure maternal and fetal safety.To aoid fetus hypoxia, urgent VV-ECMO (right femoral vein-right internal jugular vein) implantation was performed to adjust ECMO speed about 3600 revolutions per minute and blood flow about 3.6L/min. Blood oxygen saturation significantly improved compared with the previous and returned to 95%, pulse 113bpm, respiration rate 23 times per minute, blood pressure 80/54mmHg，blood gas analysis showed PH 7.38,PaO2 76.1mmHg,PaCO2 22.6mmHg, Lactate 1.8mmol/L, blood circulation gradually stable, fetal heart monitoring showed no obvious abnormality. Considering that the ECMO flow is sufficient, the blood coagulation function is not obviously abnormal, the possibility of thrombosis was small, and the follow-up patient may terminate pregnancy at any time, we took free to anticoagulation therapy for the time being.

Fetus did not enter perinatal period at 27+2 week of pregnancy, there was an intrauterine risk of fetal death at any time, and a variety of drugs had uncertain effects on the fetus, which affected the use of therapeutic drugs. Moreover, the pregnancy state itself aggravated the pulmonary load, the patient's condition was unstable, and the subsequent condition change was unpredictable. Our team decided to use Dexamethasone to promote fetal lung maturation.

Although the respiratory function of the patient improved with the assistance of ECMO, the unknown pathogen of the patient limited the use of drugs. Early termination of pregnancy can avoid long-term physical stress and may have a better maternal and infant outcome.

The clinical experience of ECMO-assisted pregnancy termination is very scarce, and it is full of clinical and ethical challenges. Considering the patient's condition rapid progression, poor respiratory function and maximumly control time, despite the risk of infection, our team chose to have a cesarean section at the bedside in ICU rather than vaginal delivery. Although vaginal delivery has been reported in the literature9,10, the duration of vaginal delivery is longer, which may increase the risk of fetal distress. Cesarean section under general anesthesia was performed at 20 hours after admission at the bedside in ICU and delivered a female live baby with an ultra-low birth weight (27+3w, 970g/34cm), and Apgar scores was 4-8-8. Intraoperative bleeding was 200ml. D-dimer began to increase to 5.89 ug/mL after operation. Heparin anticoagulation was given, and heparin dosage was adjusted to maintain APTT at 60-80s or ACT at 180-220s. The Next generation sequencing(NGS) test of bronchoalveolar lavage fluid showed that penicillin-resistant Staphylococcus aureus and Streptococcus pneumoniae were positive, and currently antibiotics were sensitive, PCT was decreased gradually.

On the 3rd day with the support of ECMO, the patient occasionally had bleeding in the nasal cavity, and the dosage of heparin was adjusted. Given the oxygenation gradually improved, we gradually decreased ECMO flow on the 4th day during ECMO. However vascular ultrasound showed right internal jugular vein thrombosis, ECMO catheter was pulled out, tracheal intubation in prone position was given to assist ventilation, and heparin anticoagulation continued. Four days later, the patient developed subrectus abdominis hematoma and existed bleeding risk, we stopped anticoagulation, and the blood coagulation parameters was improved gradually. On the 6th day after weaning ECMO, color Doppler ultrasound of lower extremities showed thrombosis in the right lower extremity.Inferior vena cava filter implantation was performed when the patient's circulation was stable. After that, the coagulation function and thrombus of the patients were continuously close monitoring, and the intravascular thrombus gradually disappeared. Eight days after ECMO extubation, the tracheal intubation was successfully extubated. The whole hospital length of stay was 33 days, ECMO was maintained for 4 days, and endotracheal intubation for 13 days，no complications such as nervous system and limb ischemia were left behind.

Discussion

Acute respiratory distress syndrome (ARDS) is a common cause of respiratory failure in critically ill patients, which is characterized by acute non-cardiogenic pulmonary edema and refractory hypoxemia within a week11. According to the severity of hypoxia, the upper limit of oxygenation index (PaO2/FiO2) lower than 300mmHg, 200mmHg and 100mmHg was respectively defined as mild, moderate and severe ARDS11,the average mechanical ventilation assistance time increased from 5 days to 9 days, and the mortality increased from 27% to 45% in turn12. Therefore, ARDS can increase the length of stay and mortality of patients. The patient in our case showed severe ARDS and type I respiratory failure on admission and was urgently transferred to ICU for endotracheal intubation and mechanical ventilation.

ECMO is an effective method to support cardiopulmonary function. It was successfully used to treat ARDS patients for the first time in 197213. Since then, the indications of ECMO have been expanding. In recent years, with the continuous improvement of ECMO technology, the clinical outcome of ECMO in the treatment of ARDS has been also improving. A multicenter randomized controlled trial (CESAR study) in the UK recommended that severe reversible ARDS patients were transferred to the ECMO center in time to use ECMO for further treatment, and the 6-month survival rate was significantly improved compared with traditional mechanical ventilation support14. Recent Meta analysis comparing the effects of VV-ECMO and conventional mechanical ventilation assistance on adult ARDS mortality and complications showed that VV-ECMO significantly reduced 60-day mortality but increased the risk of major bleeding events15. In 2009, ECMO was successfully used to treat pregnant women with ARDS caused by H1N19. When used in the treatment of pregnant women, ECMO can show a good survival outcome, a recent Meta analysis showed that ECMO treatment of maternal 30-day overall survival rate of 75.4%, 1-year overall survival rate of 74.3%, fetal survival rate of 64.7%16.

There are still many dilemmas in how to treat pregnant women with severe ARDS. Because the gestational age of pregnant women is only 27 weeks, less than 28 weeks, and fetus has not entered the perinatal period, it can not be called premature infants in medicine. The patient's condition is critical, the pathogen is unknown, the procalcitonin rises sharply, and the infection is very serious, these make our clinical decisions very difficult. The biggest dilemma is whether to prolong pregnancy to increase the probability of fetal survival or to terminate pregnancy to ensure the safety of maternal life. The condition of the pregnant woman is critical and progresses rapidly, and her life may be in danger at any time. Considering the uncertainty of the effect of drugs on the fetus, the state of pregnancy may limit the use of drugs, so we decided to terminate the pregnancy in time.

Another decision is to choose the model of delivery. The mode of delivery has a significant effect on hemodynamics. During vaginal delivery, cardiac output increases by about 35%17, while cardiac output increased by 47% during cesarean section18.Although vaginal delivery has been reported in the literature, the duration of vaginal delivery is longer than cesarean section, which may increase the risk of fetal death. Although cesarean section may further aggravate the symptoms of pneumonia, most of the patients reported in the literature were delivered by cesarean section because of the need for sedation during ECMO treatment 19-21. In order to avoid the possibility of intrauterine hypoxia, we chose cesarean section. However, at present, there is no consensus on the best gestational age for delivery22-25, and further research is needed.

In terms of anticoagulation, the blood coagulation function of the patients was normal and the flow was sufficient when ECMO was implanted. Considering the termination of pregnancy at any time and adverse effects of anticoagulation on the fetus, at the beginning, we adopted heparin-free anticoagulation strategy to closely monitor the blood coagulation function of patients. After cesarean section,the serum D-dimer of patients gradually increased, We began to use anticoagulation, adjust the dosage of heparin to maintain APTT at 60-80s or ACT at 180-220s. Oxygenation gradually improved after delivery, and considering the increased risk of bleeding and thromboembolism complications if taking long-term ECMO treatment, we gradually reduced the ECMO flow to 2L/min, but vascular ultrasound revealed right internal jugular vein thrombosis. Considering that the patient was young and oxygenation gradually improved, the use of ECMO may further increase the risk of thrombosis and thromboembolic complications, we decided to weaning from ECMO. Mechanical ventilation in prone position was given, followed by anticoagulation therapy.

In terms of complications, it can be seen from our cases that ECMO can lead to thrombocytopenia，bleeding (subrectus abdominis hematoma)， and thromboembolism (venous thrombosis) complications. However, our patient did not leave behind complications such as nervous system, limb ischemia, infection and so on.

Conclusion

Special physiological status during pregnancy may be associated with a higher risk of infection. Although the use of ECMO may increase the risk of bleeding and thromboembolism, the short-term survival benefits of ECMO may outweigh the risk of complications. In the process of clinical diagnosis and treatment of infection-related severe pneumonia during pregnancy, when conventional supportive therapy is ineffective, ECMO should be used in time to achieve ideal clinical outcome. ECMO is not only an effective advanced life support method for the treatment of severe and reversible cardiopulmonary failure, but also a feasible choice for the treatment of patients with ARDS. Due to the limited number of critical cases and the lack of clinical guidelines, ECMO placement and withdrawal, intubation strategies, delivery methods and perinatal management are all challenging, so more practical experience of experienced and multidisciplinary treatment teams are needed.

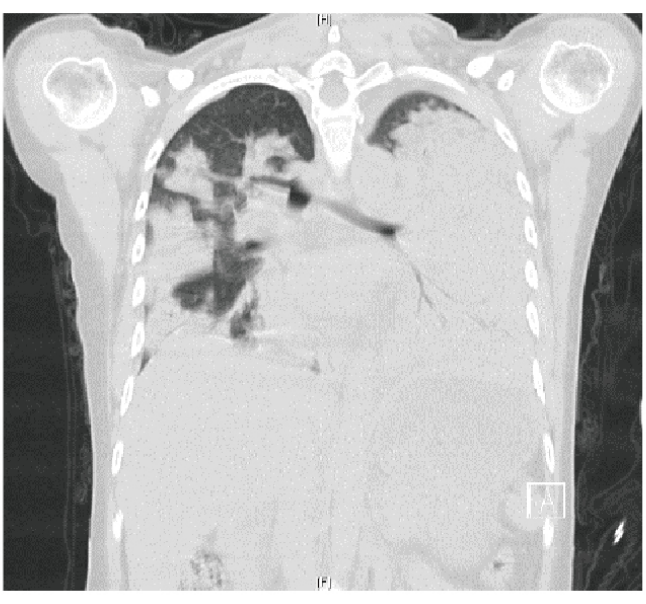

Fig.1

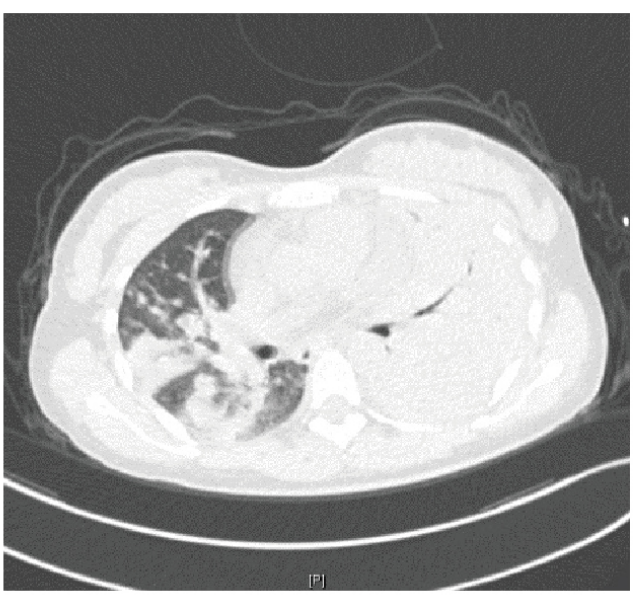

Fig.2

(Fig.1 and 2 chest CT showed bilateral diffuse lung consolidation, especially in the left lung.)

1. Chen YH, Keller J, Wang IT, Lin CC, Lin HC. Pneumonia and pregnancy outcomes: a nationwide population-based study. Am J Obstet Gynecol. 2012;207(4):288 e281-287.
2. Duarte AG. ARDS in pregnancy. Clin Obstet Gynecol. 2014;57(4):862-870.
3. MacLaren G, Combes A, Bartlett RH. Contemporary extracorporeal membrane oxygenation for adult respiratory failure: life support in the new era. Intensive Care Med. 2012;38(2):210-220.
4. Sebastian NA, Spence AR, Bouhadoun S, Abenhaim HA. Extracorporeal membrane oxygenation in pregnant and postpartum patients: a systematic review. J Matern Fetal Neona. 2020.
5. Moore SA, Dietl CA, Coleman DM. Extracorporeal life support during pregnancy. J Thorac Cardiovasc Surg. 2016;151(4):1154-1160.
6. Saad AF, Rahman M, Maybauer DM, et al. Extracorporeal Membrane Oxygenation in Pregnant and Postpartum Women With H1N1-Related Acute Respiratory Distress Syndrome: A Systematic Review and Meta-analysis. Obstet Gynecol. 2016;127(2):241-247.
7. Sharma NS, Wille KM, Bellot SC, Diaz-Guzman E. Modern use of extracorporeal life support in pregnancy and postpartum. ASAIO J. 2015;61(1):110-114.
8. ECLS Registry Report International Summary. https://www.elso.org/Registry/InternationalSummaryandReports/InternationalSummary.aspx. Accessed 8/5, 2022.
9. Radsel P, Gorjup V, Jazbec A, et al. Pregnancy complicated by influenza A ARDS requiring consecutive VV-ECMO treatment with successful vaginal delivery. J Artif Organs. 2018;21(4):471-474.
10. Kunstyr J, Lips M, Belohlavek J, et al. Spontaneous delivery during veno-venous extracorporeal membrane oxygenation in swine influenza-related acute respiratory failure. Acta Anaesthesiol Scand. 2010;54(9):1154-1155.
11. Force ADT, Ranieri VM, Rubenfeld GD, et al. Acute respiratory distress syndrome: the Berlin Definition. JAMA. 2012;307(23):2526-2533.
12. Menk M, Estenssoro E, Sahetya SK, et al. Current and evolving standards of care for patients with ARDS. Intensive Care Med. 2020;46(12):2157-2167.
13. Zapol WM, Snider MT, Hill JD, et al. Extracorporeal membrane oxygenation in severe acute respiratory failure. A randomized prospective study. JAMA. 1979;242(20):2193-2196.
14. Peek GJ, Mugford M, Tiruvoipati R, et al. Efficacy and economic assessment of conventional ventilatory support versus extracorporeal membrane oxygenation for severe adult respiratory failure (CESAR): a multicentre randomised controlled trial. Lancet. 2009;374(9698):1351-1363.
15. Munshi L, Walkey A, Goligher E, Pham T, Uleryk EM, Fan E. Venovenous extracorporeal membrane oxygenation for acute respiratory distress syndrome: a systematic review and meta-analysis. Lancet Respir Med. 2019;7(2):163-172.
16. Naoum EE, Chalupka A, Haft J, et al. Extracorporeal Life Support in Pregnancy: A Systematic Review. J Am Heart Assoc. 2020;9(13):e016072.
17. Hemnes AR, Kiely DG, Cockrill BA, et al. Statement on pregnancy in pulmonary hypertension from the Pulmonary Vascular Research Institute. Pulm Circ. 2015;5(3):435-465.
18. Langesaeter E, Dyer RA. Maternal haemodynamic changes during spinal anaesthesia for caesarean section. Curr Opin Anaesthesiol. 2011;24(3):242-248.
19. Lysenko L, Zaleska-Dorobisz U, Blok R, et al. A successful cesarean section in a pregnant woman with A (H1N1) influenza requiring ECMO support. Kardiochir Torakochirurgia Pol. 2014;11(2):216-219.
20. Panarello G, D'Ancona G, Capitanio G, et al. Cesarean section during ECMO support. Minerva Anestesiol. 2011;77(6):654-657.
21. Crawford TC, Grimm JC, Magruder JT, et al. A curious case of acute respiratory distress syndrome. J Surg Case Rep. 2015;2015(11).
22. Ong J, Zhang JJY, Lorusso R, MacLaren G, Ramanathan K. Extracorporeal membrane oxygenation in pregnancy and the postpartum period: a systematic review of case reports. Int J Obstet Anesth. 2020;43:106-113.
23. Olson TL, O'Neil ER, Ramanathan K, Lorusso R, MacLaren G, Anders MM. Extracorporeal membrane oxygenation in peripartum cardiomyopathy: A review of the ELSO Registry. Int J Cardiol. 2020;311:71-76.
24. Ramanathan K, Tan CS, Rycus P, et al. Extracorporeal Membrane Oxygenation in Pregnancy: An Analysis of the Extracorporeal Life Support Organization Registry. Crit Care Med. 2020;48(5):696-703.
25. Zhang JJY, Ong JA, Syn NL, et al. Extracorporeal Membrane Oxygenation in Pregnant and Postpartum Women: A Systematic Review and Meta-Regression Analysis. J Intensive Care Med. 2021;36(2):220-228.

Treatment of malignant airway stenosis with extracorporeal membrane oxygenation under low-dose anticoagulation：a case report

Abstract

Severe stenosis caused by lung cancer can lead to airway obstruction with a high risk of asphyxia, and the Metallic stent placement can alleviate the ventilatory obstruction. However, the risk of asphyxia during airway stenting is extremely high, and extracorporeal membrane pulmonary oxygenation (ECMO) can reduce the risk of the procedure by transiently replacing cardiopulmonary function.Systemic anticoagulation with heparin is required during ECMO, and the risk of bleeding during intraoperative operations is significantly increased. In this case report, we describe a patient with malignant central airway obstruction who was successfully treated with low-dose heparin intravenous-venous ECMO, effectively reducing intraoperative bleeding and invasive operation time, with rapid postoperative withdrawal and recovery.

Introduction

Malignant central airway obstruction can be caused by infiltration, metastasis, compression of malignant lesions in the airway lumen itself or in organs outside the airways, and the most common causes include metastasis of tumors such as lung cancer, esophageal cancer, thyroid cancer, etc.The treatment principle of which is to relieve the airway obstruction as soon as possible.Extracorporeal membrane oxygenation (ECMO) is one method that can temporarily replace the function of the heart and/or lungs over an extended period of time,maintain the oxygenation and guarantee tissue oxygen supply,provid a bridge to rescue therapy [1]. In this case, because of the high bleeding risk,the low-dose anticoagulation (LA) strategy was used, and t The final outcome as well as patient outcome were good.

Case report

A 58-year-old male(172cm 61kg BMI 20.6) was develop a symptom of progressive dysphagia in 1 years ago. After gastroscopy and histopathological examination, he was diagnosed with esophageal carcinoma by gastroscopy. The color doppler ultrasound suggested liver metastasis. He underwent a radical esophagectomy following 2 cycles of eoadjuvant chemotherapy, but refused further therapy. 1 week ago, he presented to our emergency department due to cough and shortness of breath, the non-Invasive Ventilator treatment was continuous given. CT scan showed that multiple enlarged lymph nodes in both hilum and mediastinum and an enlarged bilateral cervical lymph nod, the trachea and opening of the left and right main bronchi by the esophageal cancer with severe luminal narrowing. The presentation of fibrobronchoscopy showed narrowing of the tracheal lumen from the proximal trachea to both right and left main bronchus with nodular changes .The stenotic segment of the left main bronchus was approximately 4 cm in length,and the right main bronchus stenosis is 2.5cm.During the procedure, the nodular tissue is easy to caused significant mucosal hemorrhage(Figure1). Because of the position of stenosis involved carina and bilateral main bronchi, In acute airway collapse, which may lead to difficult to oxygenate and ventilate, meanwhile endotracheal intubation and tracheotomy could not relief of mechanical airway obstruction. After multidisciplinary consultation, we decide to utilize veno-venous extracorporeal membrane oxygenation (VV-ECMO) for temporary respiratory support to the Self-Expandable Metallic Y stent placement.

ECMO was performed using the PLS (permanent life support) system with rotaflow devices (MAQUET cardiopulmonary AG, hirrlingen, Germany), on 19 October 2021. Considering the high risk of bleeding during operation, the loading dose of heparin was 20 U/kg (intravenous). After the Activated Clotting Time of whole blood (ACT) reached 148 s, Outflow cannula via right femoral vein using 21-Fr and Inflow cannula via right internal jugular vein using 15-Fr. ECMO flow was maintained at 4.0~4.5 L/min with rotation speed 4000 rpm, and oxygen concentration 0.8, oxygen flow rate 4 L / min , SpO2 remained at 95-99% without mechanical ventilation. Bronchoscopic treatment was performed, after confirming stable vital signs. we uesd the high-frequency electric knife to cut the tumor tissue, cryotherapy to ablation,and a Y-shaped airway metallic stent under rigid bronchoscopy followed by argon plasma coagulation to achieve hemostasis(Figure2). On account of treatment duration with obviously bleed, topical thrombin and norepinephrine was uesd in endotracheal without of the maintenance heparin pump. The activated clotting time, oxygen saturation, clot in the oxygenator were closely monitored and recorded. The PaO2 levels were maintained at 80 to 120 mmHg, the PCO2 was 35 to 45 mmHg, and ACT was maintained at 108 to135 seconds. The operative time was 80 minutes with 100 ml of intraoperative bleeding. The patient's vital signs were stable with invasive mechanical ventilation(mode SIMV, PSV 14cmH2O, PEEP 5cmH2O, FiO2 100%) after operation, and ECMO parameters were reduced (rotation rate 3000 rpm, flow 4.0 L / min, oxygen concentration 0, oxygen flow 0L/ min).However, the patient's oxygen saturation could not be maintained, arterial blood gas analysis indicated SPO2 56mmHg, PCO2 48mmHg. Adjusts the ECMO parameters to rotation speed 3000 rpm, flow rate 3.5 L/min, oxygen concentration 0.6, oxygen flow rate 4 L/min. After 50 minutes support, the oxygen concentration and flow rate were gradually adjusted downward, up until kept on invasive ventilator with PSV 14 cmH2O, PEEP 5 cmH2O, FiO2 60%, and ECMO parameters with rotation rate 3000 rpm, flow 3.5 L/min, oxygen concentration 0, oxygen flow 0 L/min. Concurrent review arterial blood gas analysis with SPO2 88 mmHg and PCO2 39 mmHg.Subsequently, ECMO was withdrawn safely after 60 minutes later with SPO2 91 mmHg and PCO2 41 mmHg. The patient was successfully detoxified on October 20, 2021, and transferred back to the general ward on October 22, 2021. As of the date of publication, the patient is surviving well and is undergoing radiotherapy and systemic chemotherapy in the oncology department.

Discussion

Central airway stenosis is defined as narrowing occurring in the vocal cords, main airways and main bronchi. Currently, transbronchoscopic intervention has become the preferred method to effectively relieve malignant airway stenosis caused by various tumors[1]. However, the trachea is not only a surgical site, but also for ensuring ventilation and maintaining oxygenation. Without establish an artificial airway , part of patients could not receive further treatment. Therefore, it is recommended that the further surgical treatment with ECMO support is indicated when tracheoscopy or CT shows an endotracheal diameter of less than 5 mm[2, 3].

Since ECMO is a modification of cardiopulmonary bypass, ECMO is partially consistent with cardiopulmonary bypass in the anticoagulation strategy[4, 5].During treatment, blood contacts the non-endothelial surface of the extracorporeal circuit, a blood biosurface reaction is activated,initiating a systemic inflammatory response, and subsequent causing activation of the coagulation cascade, complement system, platelets, vWF, and fibrinolytic system[6].Therefore, anticoagulants are use to prevent thrombosis in ECMO circuits. However, inadequate anticoagulation leads to a significantly higher risk of thrombosis is mainly highlighted , which causing a series of thrombosis-related complications[7].The guidelines published by the Extracorporeal Life Support Organization (ELSO), which are now most commonly used, recommend systemic anticoagulation with heparin under ECMO support to prevent thrombosis, and an target range of 180-220 seconds for activated clotting time (ACT) , but there is no unified consensus on the target value of ACT, and guidelines vary from center to center[8].Advances in centrifugal pumps, newer polymethylpentene oxygenators and the biocompatibility of heparin-coated tubing,the risk of thrombosis and its complications have been reduced[9].However, with the increasing use of ECMO, bleeding due to anticoagulation has become the most common complication of ECMO. They mainly include intracranial bleeding, surgical site bleeding, and gastrointestinal bleeding[10, 11], and the consequences of these complications are often fatal as well. Some studies showed that bleeding in adults treated with ECMO is 27-60%[12], Overall survival to discharge for patients with bleeding complications is 33% and 67% for without bleeding complications, and that a higher activated partial thromboplastin time (aPTT) in the preoperative 24 hours was associated with the complication of bleeding[11]. Therefore, low-dose anticoagulation (LA) strategies have been proposed in order to reduce bleeding on ECMO[13-15]. Arlt et al. reported that in disastrous trauma patients support with ECMO without heparin, the incidence of bleeding can be reduced by initiating treatment without heparin and subsequently administering continuous low-dose heparin anticoagulation[16].In addition, there are reports about benefits to ECMO-assisted patients from lowering anticoagulation standards and maintaining coagulation system[14, 17]. In a meta-analysis, it was noted that the LA group had a similar risk of deep vein thrombosis and a lower incidence of gastrointestinal bleeding and surgical site bleeding compared to the standard-dose anticoagulation (SA)group, Meanwhile, including intracranial bleeding, pulmonary bleeding, and ECMO cannulation site bleeding, were not significantly different, and the probability of successful withdrawal and oxygenator replacement was not significantly different between the two groups[5].Wood-KL et al. concluded that even in the absence of systemic anticoagulation, thrombotic events in the ECMO were not increased[18], and LA has the advantages of fewer bleeding complications, fewer transfusions, and higher survival rates compared to SA strategies [19]. However, it is noteworthy that studies in which some reports still repeatedly suggest that some extent of microembolic events may occur in ECMO patients, but the clinical significance of this potential microembolic burden has not been determined[20]. Therefore, in patients with contraindications to therapeutic anticoagulation, short-term heparin-free intravenous-venous ECMO may be an effective treatment modality without thromboembolic complications[21, 22].

Due to the prolonged time of epidural bronchoscopy for airway narrowing, patients may suffer from rapid hypoxia or even death due to airway spasm, bleeding and pulmonary edema during the treatment[23], while ECMO can effectively avoid. In this case, although the patient had malignant airway stenosis, pulmonary function, vascular ultrasound, cardiac ultrasound, CT and other tests were completed preoperatively to assess the patient's general condition. Since preoperative assessment of organ function was well and the postoperative tissue oxygen supply could be maintained by an invasive ventilator, we opted for low-dose anticoagulation in anticipation of a short ECMO machine run time, although the feasibility or superiority of LA over SA remains controversial at this time. Meanwhile, high-flow (>3.5 L/min) short-term ECMO without of the maintenance heparin pump was used instead of anticoagulation during treatment. Despite the postoperative hypoxemia, it was able to be successfully withdrawn after a brief period of support, with an ECMO turnaround time of 190 minutes and no significant embolus formation on postoperative inspection of the circuit and oxygenator.

Based on the case, it is recommended that a comprehensive preoperative assessment, a prediction of the duration of ECMO, and a reasonable choice of low-dose anticoagulation can effectively reduce bleeding and invasive operation time in Central airway surgery, effectively avoid the consumption and over-activation of procoagulant and anticoagulant components, and directly reduce complications due to prolonged ECMO.

References:

[1]. Razi, S.S., et al., Timely airway stenting improves survival in patients with malignant central airway obstruction. Ann Thorac Surg, 2010. 90(4): p. 1088-93.

[2]. Kim, C.W., et al., The Feasibility of Extracorporeal Membrane Oxygenation in the Variant Airway Problems. Ann Thorac Cardiovasc Surg, 2015. 21(6): p. 517-22.

[3]. Hoetzenecker, K., et al., Extracorporeal support in airway surgery. J Thorac Dis, 2017. 9(7): p. 2108-2117.

[4]. Bartlett, R.H., et al., Extracorporeal membrane oxygenation (ECMO) cardiopulmonary support in infancy. Trans Am Soc Artif Intern Organs, 1976. 22: p. 80-93.

[5]. Lv, X., et al., Low vs standardized dose anticoagulation regimens for extracorporeal membrane oxygenation: A meta-analysis. PLOS ONE, 2021. 16(4): p. e0249854.

[6]. Esper, S.A., et al., Extracorporeal Membrane Oxygenation in the Adult. Anesthesia & Analgesia, 2014. 118(4): p. 731-743.

[7]. Bohman, J., et al., The Year in Extracorporeal Membrane Oxygenation: Selected Highlights From 2021. J Cardiothorac Vasc Anesth, 2022.

[8]. Esper, S.A., et al., Adult extracorporeal membrane oxygenation: an international survey of transfusion and anticoagulation techniques. Vox Sang, 2017. 112(5): p. 443-452.

[9]. Kurihara, C., et al., Feasibility of Venovenous Extracorporeal Membrane Oxygenation Without Systemic Anticoagulation. The Annals of Thoracic Surgery, 2020. 110(4): p. 1209-1215.

[10]. Sutter, R., K. Tisljar and S. Marsch, Acute Neurologic Complications During Extracorporeal Membrane Oxygenation: A Systematic Review. Crit Care Med, 2018. 46(9): p. 1506-1513.

[11]. Oude, L.A., et al., Hemorrhagic complications during extracorporeal membrane oxygenation - The role of anticoagulation and platelets. J Crit Care, 2019. 54: p. 239-243.

[12]. Mazzeffi, M., et al., Bleeding, Transfusion, and Mortality on Extracorporeal Life Support: ECLS Working Group on Thrombosis and Hemostasis. Ann Thorac Surg, 2016. 101(2): p. 682-9.

[13]. Prat, N.J., et al., Low-Dose Heparin Anticoagulation During Extracorporeal Life Support for Acute Respiratory Distress Syndrome in Conscious Sheep. Shock, 2015. 44(6): p. 560-8.

[14]. Wen, P., et al., Non-heparinized ECMO serves a rescue method in a multitrauma patient combining pulmonary contusion and nonoperative internal bleeding: a case report and literature review. World Journal of Emergency Surgery, 2015. 10(1).

[15]. Muellenbach, R.M., et al., Prolonged heparin-free extracorporeal membrane oxygenation in multiple injured acute respiratory distress syndrome patients with traumatic brain injury. Journal of Trauma and Acute Care Surgery, 2012. 72(5): p. 1444-1447.

[16]. Arlt, M., et al., Extracorporeal membrane oxygenation in severe trauma patients with bleeding shock. Resuscitation, 2010. 81(7): p. 804-9.

[17]. Krueger, K., et al., Venovenous Extracorporeal Membrane Oxygenation With Prophylactic Subcutaneous Anticoagulation Only: An Observational Study in More Than 60 Patients. Artif Organs, 2017. 41(2): p. 186-192.

[18]. Wood, K.L., et al., Venoarterial-Extracorporeal Membrane Oxygenation Without Routine Systemic Anticoagulation Decreases Adverse Events. Ann Thorac Surg, 2020. 109(5): p. 1458-1466.

[19]. Raman, J., et al., A comparison of low and standard anti-coagulation regimens in extracorporeal membrane oxygenation. J Heart Lung Transplant, 2019. 38(4): p. 433-439.

[20]. Marinoni, M., et al., Cerebral microemboli detected by transcranial doppler in patients treated with extracorporeal membrane oxygenation. Acta Anaesthesiologica Scandinavica, 2016. 60(7): p. 934-944.

[21]. Muellenbach, R.M., et al., Prolonged heparin-free extracorporeal membrane oxygenation in multiple injured acute respiratory distress syndrome patients with traumatic brain injury. J Trauma Acute Care Surg, 2012. 72(5): p. 1444-7.

[22]. Lamarche, Y., et al., Thromboembolic events in patients on extracorporeal membrane oxygenation without anticoagulation. Innovations (Phila), 2010. 5(6): p. 424-9.

[23]. Hasdiraz, L., et al., Complications of bronchoscopy for foreign body removal: experience in 1,035 cases. Ann Saudi Med, 2006. 26(4): p. 283-7.

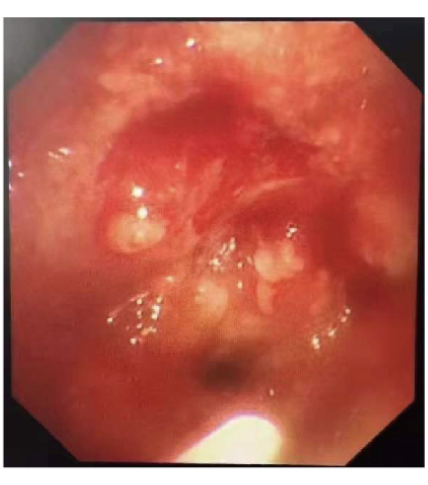
图1

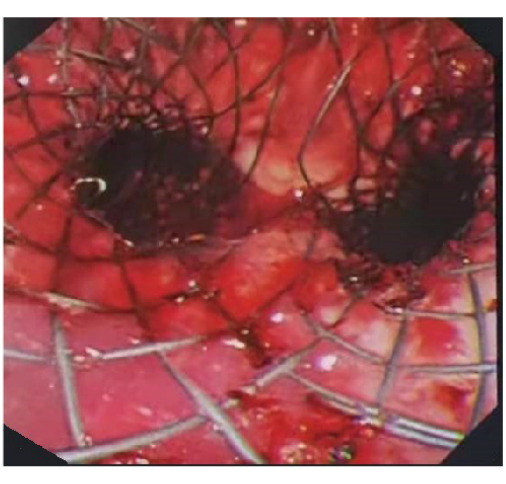
图2

第6届中国医师协会体外生命支持年会
The 6th Chinese Society of ExtraCorporeal Life Support Annual Meeting

体外膜肺氧合治疗院外心脏骤停1例

屈文静[1] 卢安东[2] 白明[2]

（1. 兰州大学第一临床医学院，甘肃省兰州市 730000; 2. 兰州大学第一医院心脏中心/甘肃省心血管疾病重点实验室，甘肃省兰州市 730000;
3. 冠心病诊疗甘肃省国际合作基地，甘肃省兰州市 730000）

【关键词】院外心跳骤停；体外膜肺氧合；经皮冠状动脉介入治疗

【摘要】

背景：院外心脏骤停是严重威胁人民群众安全的危急情况。研究表明，心跳骤停急救的“黄金时间”只有4-6分钟，每延迟1分钟，心肺复苏的成功率就下降10%，尽管近几年公共场所除颤设备以及群众心肺复苏技术逐渐普及，院外心脏骤停的患者存活率仍然很低。

患者：在本文中，我们报告了一位43岁男性，突发胸闷，胸痛1小时，意识丧失半小时。

诊断：患者初步被诊断为院外心脏骤停合并难治性心室颤动。

干预：患者院外心跳骤停至体外循环成功建立共用时58分钟，后急诊行冠状动脉造影示：前降支完全闭塞，TIMI血流0级，于前降支植入1枚支架，冠脉血流量恢复到TIMI Ⅲ级。

预后：患者完全痊愈后出院，无神经功能障碍，无并发症。

结论：院外心跳骤停患者经传统心肺复苏超过40分钟的神经功能良好存活者非常罕见，但ECPR可以明显增加这种患者的生存率。

简介

成人院外心跳骤停的发病率平均为95.9/10万/年[1]，其死亡率也居高不下，出院时存活率仅为5-15%[2]，而且幸存的患者中有很大一部分遗留有神经功能障碍。近年来院外心跳骤停患者存活率的升高与公众场所除颤器以及心肺复苏技术的普及显著相关[3]。院外心跳骤停最常见的原因为急慢性冠状动脉疾病以及心肌病，例如急性冠脉综合征，肥厚性心肌病，扩张型心肌病等，其中以急性心肌梗死最为常见。心脏骤停是急性心肌梗死的严重并发症。随着介入技术应用以来，心肌梗死的住院死亡率明显下降，但心肌梗死患者合并院外心脏骤停的死亡率仍然很高。静脉-动脉体外膜肺氧合(VA ECMO)已经成为对传统心肺复苏无效的院外心脏骤停患者的抢救策略[4-7]。本文报道了1例院外心跳骤停合并难治性室颤的患者，发病后58分钟建立了体外循环，经ECPR和急诊PCI治疗后痊愈出院。

病例资料

患者，男性，43岁，主因“胸闷，胸痛1小时，意识丧失30分钟”于2020年12月24日入院前1小时突然出现胸闷、胸痛，伴有出汗和烦躁，半小时后失去意识，对外界刺激没有反应，其家属立即拨打了120急救电话，急救人员通过电话指导家属进行人工胸外按压，在驱车前往现场的同时联系ECMO团队做好接诊准备。现场行心电图提示：心室颤动心律。急救人员立即展开抢救，非同步直流电击除颤以及简易气囊辅助呼吸等，但患者并未恢复自主窦性心律，持续胸外按压并将患者转运至急诊科。与此同时，ECMO团队电话联系经治医生进一步详细了解患者病情。病人到达急诊科时还未恢复自主心率，在急诊科行气管插管并给予无创呼吸机辅助呼吸，静脉注射肾上腺素及电击除颤等抢救后患者仍为室颤心律。实验室检查示：PH值：7.1，乳酸12.6 mmol/L，二氧化碳分压20 mmHg，BE-12 mmol/L，心肌肌钙蛋白I：0.95 ng/mL。ECMO团队成员在床旁超声的辅助下定位股动脉穿刺点，于右侧股动、静脉分别插入17F和21F股动脉和股静脉鞘管，22分钟后VA-ECMO已经正常运行。在体外膜肺氧合的辅助下，患者的血流动力学得到改善，自主心律得以恢复。整个过程仅用时58分钟。

虽然患者暂时的恢复了自主心律，但心跳骤停的原因尚未明确，患者仍持续出现室性心律，随时可能再次出现心跳骤停。患者此次发病前体健，有长期大量吸烟史，其余无特殊病史，根据患者的病史及临床经验，我们怀疑该患者是由于急性心肌梗死所导致的院外心跳骤停，目前治疗急性心肌梗死的最佳方法就是经皮冠状动脉介入资料使心肌得到再灌注，从而缩小心肌坏死的面积，改善患者预后。病人当时正处于介入治疗的窗口，于是立即将患者送往导管室，行冠状动脉造影(CAG)示左前降支完全闭塞，冠状动脉血流TIMI为0级(图1左)，患者明确诊断为急性心肌梗死。在ECMO辅助下将支架置入患者前降支，冠脉血流恢复至TIMI Ⅲ级(图1右)。术后在心血管重症监护病房行下一步治疗，给予冰帽低温脑保护、甘露醇脱水、激素、营养心肌、抗血小板、抗凝、早期镇静、镇痛等治疗。3天后VA-ECMO成功脱机，患者血流动力学稳定。5天后拔除患者气管插管。两周的治疗后，患者各方面均好转，从重症病房转入普通病房观察后痊愈出院。

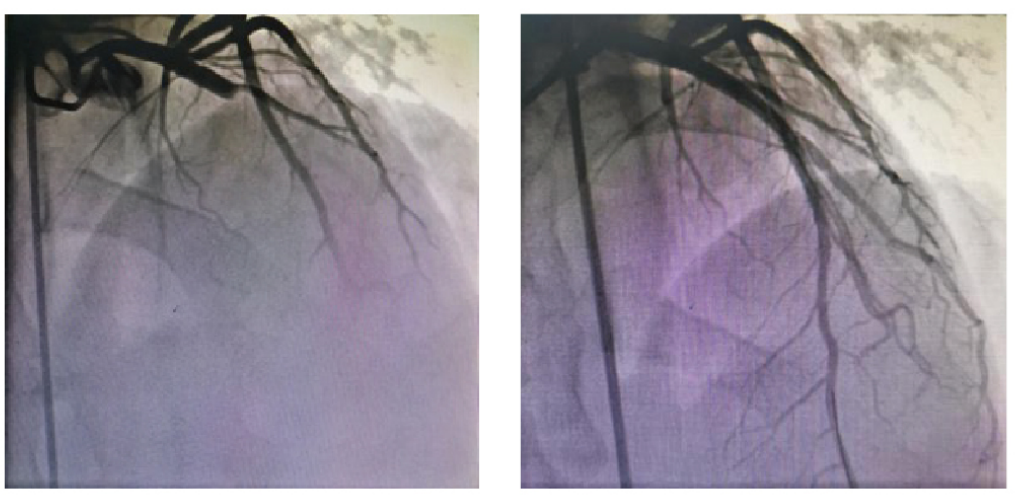

图一 左，冠脉造影示前降支完全闭塞；右，支架植入后患者冠脉血流恢复TIMI III级

讨论

在过去的二十年中，体外膜氧合(ECMO)已经成为难治性心脏骤停患者的选择[4]。早期观察性研究发现，与传统CPR相比，ECPR可提高75岁以下有潜在可逆性条件的75岁以下心脏骤停患者的存活率[8, 9]。E-CPR通常指的是，在体外胸外按压继续进行的同时，在超声的引导下在人体大的动静脉内置入管路，患者大部分血液从静脉引流出来，经过体外的机械泵，迫使血液通过氧合器带入一定的压力再注入动脉，以灌注重要的器官和组织，代替心肺功能。根据体外生命支持组织(ELSO)的官方报告，到目前为止，全球已有11798例成人ECPR，存活率为30%[10]。据统计，我国成人ECPR住院存活率为26%[11]。但这些病例大多是发生在医院的心脏骤停。而院外心跳骤停在58分钟的传统心肺复苏后，存活并且神经功能完好的患者非常罕见，我国之前未见类似报道。ECPR可以产生有效的冠状动脉和器官组织灌注[7]，是通向治疗的桥梁。

甘肃急性心梗救治网络将120急救中心、急诊科和ECMO团队紧密联系在一起，这是前所未有的。我们的ECMO团队包括1名领队、2-3名专业的医生和1名训练有素的护士，随时可提供循环支持，ECMO的地理足迹遍及整个甘肃省，为危重患者提供了生命的希望，极大地提高了ECMO的易用性。所有医务人员都在早期阶段接受了培训，随时

做好出诊准备，极大地缩短了急救时间。当病人处于“OH-RED”(图2)标准下，急救中心立即电话联系ECMO Team并将病人的基本情况以及信息发送至微信群，持续进行高效CPR，将病人转运回急诊科。同时，ECMO团队在接到通知后，立即召集专业人员，准备设备及耗材等，前往急诊科等待病人。病人到达医院后，ECMO团队在2-3min内迅速评估患者有无ECMO禁忌症。若此时患者已经恢复自主循环及意识，则无需ECMO辅助。

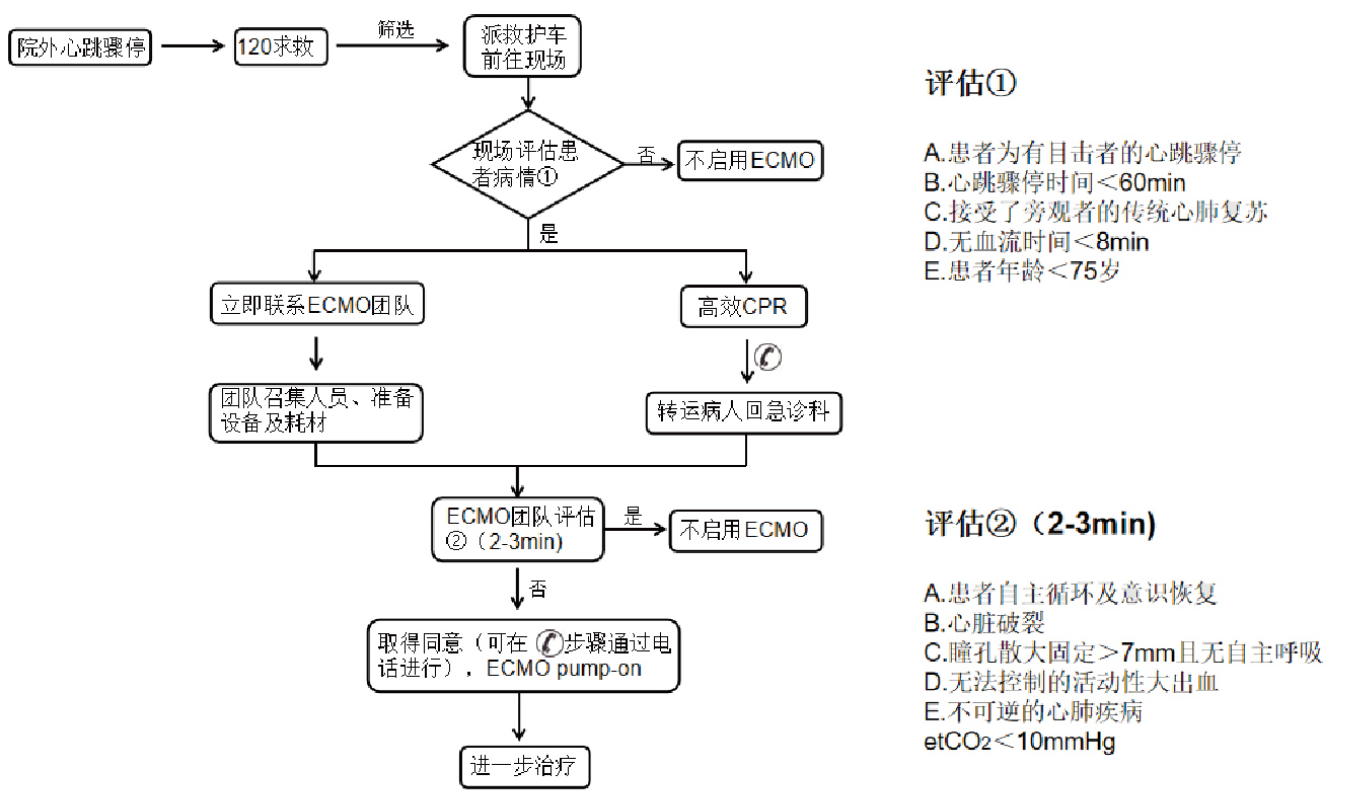

图二 OH-RED

传统的心肺复苏仅产生正常心输出量的25-30%[12]。这种“低流量”状态存在的时间越长，冠状动脉灌注压就越不充足，自主循环恢复的机会越小，发生不可逆转的多器官衰竭(包括缺氧性脑损伤)的可能性就越大。体外心肺复苏术不仅有助于存活率的提高，也可能在一定程度上对神经功能的良好预后有一定的改善作用。研究表明，旁观者立即进行心肺复苏比等待医疗机构到达现场后再进行心肺复苏神经功能预后更佳[13]，对于心肺复苏超过30分钟仍没有恢复自主循环的患者，ECLS产生了神经功能上有益的存活率[4, 6]。在接受心肺复苏超过21分钟的患者中，ECPR比CCPR有更好的效果，ECLS应该在心脏骤停后早期进行，而不是在CCPR方法完全失效之后[14]。在大多数难治性VT/VF患者中，大约80%的患者表现为急性心肌缺血，早期冠状动脉血运重建与存活率和良好的神经预后相关[15]。因此，对于院外心跳骤停患者来说，时间是极其宝贵的，这需要跨学科的合作。这一模式应该得到越来越多的应用，以挽救更多的患者。

参考文献

[1] Porzer M, Mrazkova E, Homza M, et al. Out-of-hospital cardiac arrest[J]. Biomed Pap Med Fac Univ Palacky Olomouc Czech Repub, 2017,161(4):348-353.

[2] Nichol G, Thomas E, Callaway C W, et al. Regional variation in out-of-hospital cardiac arrest incidence and outcome[J]. JAMA, 2008,300(12):1423-1431.

[3] Blewer A L, Ho A, Shahidah N, et al. Impact of bystander-focused public health interventions on cardiopulmonary resuscitation and survival: a cohort study[J]. Lancet Public Health, 2020,5(8):e428-e436.

[4] Han K S, Kim S J, Lee E J, et al. Experience of extracorporeal cardiopulmonary resuscitation in a refractory cardiac arrest patient at the emergency department[J]. Clin Cardiol, 2019,42(4):459-466.

[5] Poppe M, Schriefl C, Steinacher A, et al. Extracorporeal cardiopulmonary resuscitation at the emergency department: A retrospective patient selection evaluation[J]. Eur J Anaesthesiol, 2020,37(4):280-285.

[6] Yannopoulos D, Bartos J, Raveendran G, et al. Advanced reperfusion strategies for patients with out-of-hospital cardiac arrest and refractory ventricular fibrillation (ARREST): a phase 2, single centre, open-label, randomised controlled trial[J]. Lancet, 2020,396(10265):1807-1816.

[7] Hsu C H, Meurer W J, Domeier R, et al. Extracorporeal Cardiopulmonary Resuscitation for Refractory Out-of-Hospital Cardiac Arrest (EROCA): Results of a Randomized Feasibility Trial of Expedited Out-of-Hospital Transport[J]. Ann Emerg Med, 2021,78(1):92-101.

[8] Chen Y S, Chao A, Yu H Y, et al. Analysis and results of prolonged resuscitation in cardiac arrest patients rescued by extracorporeal membrane oxygenation[J]. J Am Coll Cardiol, 2003,41(2):197-203.

[9] Kim S J, Kim H J, Lee H Y, et al. Comparing extracorporeal cardiopulmonary resuscitation with conventional cardiopulmonary resuscitation: A meta-analysis[J]. Resuscitation, 2016,103:106-116.

[10] Thiagarajan R R, Barbaro R P, Rycus P T, et al. Extracorporeal Life Support Organization Registry International Report 2016[J]. ASAIO J, 2017,63(1):60-67.

[11] 李呈龙, 侯晓彤, 黑飞龙, 等. 2018中国体外生命支持情况调查分析[J]. 中华医学杂志, 2019(24):1911-1915.

[12] Barsan W G, Levy R C. Experimental design for study of cardiopulmonary resuscitation in dogs[J]. Ann Emerg Med, 1981,10(3):135-137.

[13] Kitamura T, Kiyohara K, Nishiyama C, et al. Chest compression-only versus conventional cardiopulmonary resuscitation for bystander-witnessed out-of-hospital cardiac arrest of medical origin: A propensity score-matched cohort from 143,500 patients[J]. Resuscitation, 2018,126:29-35.

[14] Kim S J, Jung J S, Park J H, et al. An optimal transition time to extracorporeal cardiopulmonary resuscitation for predicting good neurological outcome in patients with out-of-hospital cardiac arrest: a propensity-matched study[J]. Crit Care, 2014,18(5):535.

[15] Vaillant C, Leurent G, Garlantezec R, et al. Coronary angioplasty is associated with a better neurological outcome in the era of modern management of out-of-hospital cardiac arrest[J]. Int J Cardiol, 2013,169(5):e91-e92.

VA-ECMO用于运动神经元病合并脓毒症休克的治疗1例

单位：北医三院延安分院（延安市中医医院） 作者：武志锋张天花白龙王婷婷贺小龙

摘要

这是1 例疑诊运动神经元病合并气管食管瘘、血流感染及脓毒症休克(septic shock,SS)的患者，本报道旨在讨论该气管食管瘘合并SS 患者从VA-ECMO 辅助中获益情况，以供临床医师在类似患者的治疗中参考。

引言

运动神经元病为罕见病，此类患者因后期长时间留置气管切开套管，往往导致气管食管瘘，但合并血流感染及脓毒症休克患者更为罕见。SS 是脓毒症的一个亚型，是循环和细胞代谢异常的最关键阶段[1]。在过去的十几年间，先后发布五次“拯救脓毒症”国际指南[2-6]，以期降低病死率，但由于脏器灌注受损和多脏器功能衰竭，脓毒性休克患者的病死率仍居高不下。究其原因，在发展到难治性SS 时，除优化液体治疗以及应用血管活性药物外，尚无其他的有效循环支持手段。近年来，随着体外膜肺氧合(extracorporeal membrane oxygenation,ECMO)技术的发展，以及其在危重症患者中的应用推广，使得我们逐渐VA-ECMO 的应用扩展到严重脓毒症的治疗中。对于传统治疗无效的成人脓毒症， 关于ECMO 作为“补救性”治疗应用的报道也越来越多[7-8]，被认为具有良好的疗效。

病例资料：

患者袁某，男，54 岁，身高170cm，体重：65Kg，职业：居民。

入院日期：2021 年12 月17 日

主诉：双上肢无力、肌肉萎缩1 年余。

现病史：患者1 年余前无明显原因出现双上肢无力、肌肉萎缩症状，主要表现为手指活动欠灵活，无法完成伸直、握拳动作，无法正常使用筷子，前胸及四肢有游走性肌肉跳动，手指间断出现抽痛、痉挛现象。双下肢力量正常，但自觉身体沉重，行走速度减慢，双脚踩地时有踩棉花感，同时有发音含混，饮水呛咳，吞咽偶有困难。2021 年4 月份于中国人民解放军第四军医大学唐都医院住院治疗，诊断“运动神经元病（可能）、2 型糖尿病”，予以改善循环，营养神经，降血糖等住院治疗。1 月前患者于西京医院住院治疗期间因呼吸衰竭行经口气管插管接呼吸机辅助呼吸，期间患者出现颈部脓肿，遂给予行脓肿引流及气管切开，给予“万古霉素1g bid”抗感染治疗12 日后病情改善，遂办理出院后入我科进一步治疗。

既往史：发现2 型糖尿病病史5 年余，口服二甲双胍，家中监测血糖，控制在7-12mmol/1;2021年1 月诊断为“慢性阻塞性肺疾病”，治疗后好转。

个人史：吸烟30 余年，3-5 天/包；饮酒，2 两-1 斤/日。

家族史：父亲已故，母亲及弟弟均患有糖尿病。

入院查体：T:36.3℃,P:103 次 / 分，R:15 次 / 分，BP:105/78mmHg，神志清楚，精神可，颈部留置脓肿负压引流管两根，局部无明显渗出，引流通畅；颈部留置气管切开套管，局部切口发红，可见痰液及脓液漏出，漏斗胸，双肺叩诊呈清音，双肺呼吸音清，双肺未闻及干湿啰音。心率103 次 / 分，律齐，各瓣膜听诊区未闻及病理性杂音。腹部查体无明显异常。留置尿管，尿液呈淡血性，可见少量血凝块，双下肢无水肿。四肢肌力肌张力正常，双侧膝腱反射无亢进或减弱，双侧巴彬斯基征阴性。

入院检查：

血沉：ESR 6.00 mm/h，降钙素原测定：PCT 0.133 ng/mL，心肌酶谱：CK 14.00 U/L，肾功电解质：UA 184.00 umol/L、β 2-MG 4.09 mg/L、K 2.92 mmol/L，N末端脑利肽前体：NT-proBNP111.20 pg/mL，凝血四项 + 纤溶：FIB 5.06 g/L、D-Dimer1.22 ug/ml，血常规 + 五分类：WBC5.03x10^9/L、NEUT% 72.1%、RBC 4.29x10~12/L、HGB 130.0 g/L、PLT 134.0x10^9/L脓液细菌培养：咽峡链球菌。口腔、胸部、颈椎CT(2021-12-21 本院)示:1.颈椎退行性变2.右侧颈部引流术后，周围软组织肿胀，未见明确液性密度影，请结合临床3.气管插管术后，气管食管瘘?4.右上胸腔局部脓肿形成可能5.双肺下叶感染伴部分肺不张。

入院诊断：1.运动神经元病肌萎缩侧索硬化疑诊2.颈部脓肿3.双肺炎症4.2 型糖尿病5.周围神经病6.颈动脉粥样硬化斑块形成7.上肢静脉血栓形成8.双侧股浅静脉血栓形成9.慢性结肠炎10.右肾结石

入院后治疗情况：1.抗感染：哌拉西林钠他唑巴坦钠2.营养支持：肠外营养序贯肠内（空肠管）营养3.创面换药4.呼吸支持：气管切开处接呼吸机5.支气管镜检查（确诊气管食管瘘）及促进痰液引流6.调整气管导管深度7.抗凝治疗等。

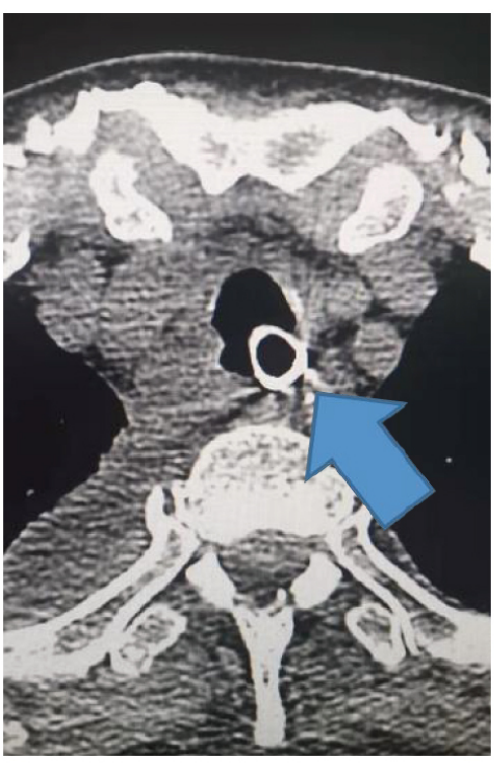

病情进展：入院第41 天，患者呼吸困难加重，出现人机对抗、寒战、高热、休克。CRP:255.1mmol/L；PCT>100ng/mL，血细菌培养回报：肺炎克雷伯菌（多重耐药），给予大剂量血管活性药物（去甲肾上腺素：4ug/kg.min）循环仍难以维持。征得患者家属同意后立即实施VA-ECMO 辅助（回输管：16F 置入深度15cm，引流管：22F 置入深度35cm，远端灌注管：6F 全部置入）ECMO 参数（转速：2500rpm 2L/min，FiO2：100%，气流量：3L/min）；加强抗感染（亚胺培南西司他丁钠1g q6h 联合硫酸粘菌素50 万单位tid）。

补充诊断：1.气管食管瘘2.血流感染3.感染性休克。

VA-ECMO 辅助4 天后，患者病情好转，体温正常，PCT 降至10.74ng/L，呼吸机参数下调，自身尿量增加，血管活性药物剂量下调（去甲肾上腺素：0.6ug/kg.min）。将ECMO 转机流量降至10-20ml/kg.min，试验性脱机，患者循环及呼吸相对稳定，遂给予撤除VA-ECMO辅助，继续血管活性药物维持循环，呼吸机辅助呼吸，维持患者生命体征相对稳定。

预后：

患者VA-ECMO 撤机两天后因气道原因突发呼吸心跳骤停，虽经积极心肺复苏抢救成功，最终患者家属放弃治疗。

讨论：

运动神经元疾病(motor neurone disease, MND)是一种影响大脑和脊髓的神经退行性疾病。MND 主要是运动神经元的退化, 导致肌肉无力。MND 是一种可以累及任何年龄段的成年人的疾病。它在55-79 岁中最常见, 40 岁以下的发病并不常见。造成MND 的原因不详，大约5% -10% 的MND 患者有该病的家族史，并且已经确定了几个异常基因。MND 的临床表现各不相同：(1)肌肉无力、消瘦、痉挛和手臂和/或腿部僵硬。(2)言语和/或吞咽问题。(3)呼吸衰竭。随着疾病的逐渐进展，其症状和体征逐渐变得典型，患者往往会出现手臂和腿部肌肉无力，吞咽和沟通障碍及呼吸肌无力，最终导致死亡。[9]大多数MND 患者在出现症状后的2-3 年内死亡，但25% 的人在5 年内存活，5% -10% 的人在10 年内存活。其中，最常见的MND 类型是肌萎缩侧索硬化症(amyotrophic lateral sclerosis，ALS)。有些较为罕见的MND 类型，如进行性肌肉萎缩或原发性侧索硬化症，其进展速度可能较慢。每个MND 患者都有其独特的疾病进展，大约10% -15% 的MND 患者会有额颞叶痴呆的表现，进而导致认知功能障碍等问题。还有约35% 的MND 患者会表现出轻微的认知障碍。

MND 所致的进行性肌无力，最初可能表现为单一和无法解释的症状。这些症状可包括：(1)肌无力，比如灵活性丧失，跌倒或绊倒；(2)言语或吞咽功能障碍，或者舌部肌束

震颤(所谓的延髓表现)；(3)肌肉方面的症状，比如无力、萎缩、抽搐、痉挛和僵硬；(4)呼吸方面的症状，比如用力时气短或难以解释的呼吸道症状；(5)呼吸功能减退的影响，比如日间过度嗜睡、疲劳、清晨头痛或躺卧时气短。[10]本例患者1 年前无明显原因出现双上肢无力、肌肉萎缩症状，主要表现为手指活动欠灵活，无法完成伸直、握拳动作，无法正常使用筷子，前胸及四肢有游走性肌肉跳动，手指间断出现抽痛、痉挛现象。双下肢力量正常，但自觉身体沉重，行走速度减慢，双脚踩地时有踩棉花感，同时有讲话发音较前含混，饮水呛咳，吞咽偶有困难。患者在住院治疗期间出现呼吸衰竭，经口气管插管后入住重症医学科，其疾病演变过程及临床表现符合MND 终末期的症状及体征。此外，因患者既往存在2 型糖尿病，血糖控制不理想，在经口气管插管接呼吸机辅助呼吸的过程中并发颈部脓肿，导致患者必须早期行气管切开。入院初期，患者的病情曾一度改善及停用抗生素。但疾病后期，随着气管食管瘘症状加重，患者出现呼吸机辅助呼吸期间反复胃胀气等可疑瘘口增大的临床表现，最终出现血流感染及SS，均系气管食管瘘导致。SS 患者出现血管低反应性，一方面是由于血管收缩剂和血管舒张剂介质之间的不平衡; 另一方面，血管对儿茶酚胺、AVP 和血管紧张素II 的反应性可能降低，尤其是儿茶酚胺"脱敏"现象，也使得血管出现低反应性。而各种血管舒张因子，例如:一氧化氮(NO)、肿瘤坏死因子α(TNF-α)、激肽和前列腺素] 也在脓毒症期间释放，以及内源性过氧亚硝酸盐、超氧阴离子和前列环素产生增加; ATP 敏感性钾通道(K-ATP)的激活; 糖皮质激素不足等使得血管舒张作用增强，使得血管处于麻痹状态，出现血管对升压药物反应性降低。[11]ECMO 可提供呼吸和(或)循环支持，通过以下方面治疗脓毒症: ①改善机体缺氧、纠正酸中毒和肺过度通气，降低肺血管阻力，改善心肌氧合，改善心功能; ②通过直接的循环支持，降低右心前负荷，改善右心功能，并增加循环灌注，改善脏器的缺血缺氧性损伤。本例患者出现SS 后经积极VA-ECMO 辅助及抗感染治疗，感染指标下降，循环及呼吸功能改善，并且顺利撤除VA-ECMO，其治疗在一定程度上是成功的，但最终患者因气道原发病导致呼吸心跳骤停，仍未能改变其最终预后，故笔者建议此类患者行VA-ECMO 辅助仍需充分考虑患者及家属的个体差异，谨慎制定诊疗方案。

结论：VA-ECMO 可以为机体提供循环及呼吸辅助，维持循环的同时也降低了呼吸机参数，降低了呼吸机相关并发症风险，保证重症感染患者全身的氧供。本例患者采用VA-ECMO辅助后循环逐渐趋于稳定，血管活性药物剂量下降，为后续的抗感染治疗争取了时间。这种VA-ECMO 保障下的抗感染治疗模式在重症感染患者中的使用是可行的，但其总体有效性及对于患者生存率的影像仍需要大样本的临床研究加以佐证，值得进一步探究。

参考文献：

[1]Singer M, Deutschman CS, Seymour CW, et al. The third international consensus defifi nitions for sepsis and septic shock (Sepsis-3)[J]. JAMA, 2016, 315(8): 801-810. DOI:10.1001/jama.2016.0287.

[2] Dellinger RP, Carlet JM, Masur H, et al. Surviving Sepsis Campaign guidelines for management of severe sepsis and septic shock[J]. Crit Care Med, 2004, 32(3): 858-873. DOI:10.1097/01.ccm.0000117317.18092.e4.

[3] Dellinger RP, Levy MM, Carlet JM, et al. Surviving Sepsis Campaign: international guidelines for management of severe sepsis and septic shock: 2008[J]. Crit Care Med, 2008, 36(1): 296-327. DOI:10.1097/01.CCM.0000298158.12101.41.

[4] Dellinger RP, Levy MM, Rhodes A, et al. Surviving sepsis campaign: international guidelines for management of severe sepsis and septic shock: 2012[J]. Crit Care Med, 2013,41(2):580-637. DOI: 10.1097/CCM.0b013e31827e83af

[5] Rhodes A, Evans LE, Alhazzani W, et al. Surviving Sepsis campaign: international guidelines for management of sepsis and septic shock: 2016[J]. Crit Care Med, 2017, 45(3): 486-552. DOI:10.1097/CCM.0000000000002255.

[6] Evans L, Rhodes A, Alhazzani W, et al. Surviving Sepsis campaign: international guidelines for management of sepsis and septic shock 2021[J]. Crit Care Med, 2021, 49(11): e1063-e1143. DOI:10.1097/CCM.0000000000005337.

[7] Park TK, Yang JH, Jeon K, et al. Extracorporeal membrane oxygenation for refractory septic shock in adults[J]. Eur J Cardiothorac Surg, 2015, 47(2): e68-e74. DOI:10.1093/ejcts/ezu462.

[8] Huang CT, Tsai YJ, Tsai PR, et al. Extracorporeal membrane oxygenation resuscitation in adult patients with refractory septic shock[J]. J Thorac Cardiovasc Surg, 2013, 146(5): 1041-1046. DOI:10.1016/j.jtcvs.2012.08.022.

[9]Centre N."Motor neurone disease assessment and management.". 2019

[10] Centre N ."End of life care for adults: service delivery".2019.

[11]体外膜肺氧合——成人难治性脓毒症休克治疗的利器；中华急诊医学杂志；2022年2 月第31 卷第2 期

体外膜肺氧合救治1例急性爆发性心肌炎患儿的护理

杨宝义[1]　李龙倜[2]　汪 蓉[1]　赵晓云[3]
十堰市太和医院（湖北医药学院附属医院）
1重症医学科　2护理部　3儿童重症医学科

【摘　要】总结1例急性爆发性心肌炎患儿的护理经验。护理主要内容如下：组建多学科团队、共同制定诊疗方案；体外膜肺氧合过程中精细化的容量管理、抗凝管理、呼吸机管理；对患儿实施个性化营养支持；加强并发症的预防和管理。经过积极的治疗和护理，患儿恢复良好，顺利转出监护室。

【关键词】体外膜肺氧合；爆发性心肌炎；护理

急性爆发性心肌炎（Acute Fulminant Myocarditis，AFM）是儿科一种较为常见的起病急、进展快、预后差疾病。其主要临床表现大多为致命性的恶性心律失常、心泵衰竭及心源性休克，可在短时间内进展至多器官功能衰竭甚至心跳呼吸骤停[1-2]。如得不到及时有效的救治，病死率可高达75%。目前传统的治疗方法很难达到理想效果。体外膜肺氧合(Extracorporeal Membrane Oxygenation，ECMO)可以为严重心肺功能衰竭的患者提供部分或全部支持，使受损脏器获得充分的休息时间，能显著提高心肺功能衰竭患者的生存率[3-4]。但国内儿童ECMO技术起步晚于成人，经验与技术相对不足，在开展过程中任有许多需要注意的地方。2021年12月，十堰市太和医院儿童重症监护室（Pediatric Intensive Care Unit，PICU）应用静脉-动脉（V-A）ECMO成功救治 1例急性爆发性心肌炎患儿，效果满意。现报告如下：

1 一般资料

患儿，男，10岁1个月，42kg，因“腹痛、纳差伴精神差3天，呕吐6次”于2021年12月23日20:08由外院转入PICU。转入时患儿精神极差，心音低钝，血压82/56mmHg，四肢末梢发绀、发凉。入院后检查结果示：白细胞计数9.60×109/L，中心粒细胞百分比71.1%，谷丙转氨酶122U/L，谷草转氨酶321U/L，血尿酸491.00umol/L，尿素氮17.34mmol/L，肌酸激酶1496IU/L，肌酸激酶同工酶227IU/L，B型脑钠肽原前体6333.2ng/L，超敏肌钙蛋白 19.58ng/ml。心电图：加速性交界性自主心律；Ⅱ、Ⅲ、avF异常Q波；ST-T改变（STV1 V2 V3 V4弓背上抬0.1～0.8mV，STV5 V6水平型下移0.1～0.2mV）；V1呈R型且ST段抬高，心脏彩超未见明显心脏瓣膜及心肌病变。初步诊断：心源性休克，暴发性心肌炎，多器官功能障碍综合征。

2021年12月23日　21:40患儿心电监护提示室性心律，心率130次/分，立即行心电图检查，结果提示：宽QRS波群心动过速；ST-T改变（STV1　V2　V3弓背上抬0.5～0.8mV，TV2　V3高尖）。立即给予利多卡因30mg静推，未转为窦性心律，心电监护仍可见多形性室性心律，21:47给予电除颤1次，患儿仍为持续性室性心律，心率波动在100-130次/分，21:50给予胺碘酮150mg缓慢静推，患儿转为窦性心律，持续2秒钟左右再次转为室性心律，遂给予持续胺碘酮静脉维持，心率波动在60-80次/分，血压波动在60-85/45-55mmHg。22:10紧急进行全院大会诊后拟行ECMO治疗。23:27与家长沟通病情后行气管插管接有创呼吸机辅助通气，行V-A ECMO治疗。ECMO治疗期间转速维持在2590转/min，血流量2.56L/min左右，氧浓度：60%，给氧流量3L/min。同时给予充分的镇静镇痛、大剂量激素冲击治疗、静丙针支持治疗、抗感染、抗病毒、保护脏器、抗心律失常、抗凝、营养心肌等治疗。

2 结果

ECMO上机后患儿病情逐渐好转，顺利运转82h后，于2021年12月27日09:34成功撤机，于2021年12月30日转至普通病房治疗，于2022年1月4日康复出院。

3 护理体会

3.1 高效的多学科协作团队是ECMO成功的基础　该患儿病情进展迅速，且我院儿童ECMO救治经验不多，因此，在医务处的指导下迅速组建了针对该患儿的多学科协作团队。该团队由23人组成，包括医务处、护理部、PICU、重症医学科（Intensive Care Unit，ICU）、胸心大血管外科、 儿科、超声影像科、康复科、药学部等相关科室。其中医务处负责现场的统筹协调，护理部负责患儿日常及ECMO护理工作，ICU医护专家负责监测ECMO期间参数变化情况及并发症的发生情况，儿科专家主要负责患儿治疗方案的决策及落实，胸心大血管外科专家负责ECMO导管的置入及侧枝循环的建立，超声科医师负责通过每日床旁超声评估患儿心脏功能，影像科医师负责通过每日床边X线检查评估患儿肺脏功能，康复科医师负责患儿整个治疗过程中的早期康复治疗，药学部医师负责指导患儿用药及、监测药物效果及不良反应。整个ECMO多学科协作团队以直接管理ECMO的医护团队为主导，其他各科室以某个技术点或疾病过程的诊治给予协助。

3.2 精细化的管理是患儿得以救治的关键　虽然近年我国儿科ECMO 技术发展迅速，但经验积累少且地域差异较大，规范仍未建立，并发症发生率、病死率及残疾率等仍相对较高[5]，因此需要我们在治疗过程中更加的精细化。

3.2.1　容量管理：由于V-A　ECMO提供血流大部分为非搏动灌注，中心静脉压（CVP）、有创动脉压（ABP）等血流动力学不易稳定[6]，给容量监测及管理带来一定难度。该患儿在ECMO上机后的第一个24h，为了纠正内环境失衡、维持ECMO流量稳定，需要足够的容量。因此，机体处于正平衡状态。我们根据患儿心脏超声评估结果和每小时出入量情况，在量出为入的基础上，遵医嘱适当给患儿补液，但严格控制输液速度，以每小时均速负平衡0～10ml为目标。并密切观察患儿心率、血压、CVP、尿量、肢端灌注、乳酸水平及ECMO的流量变化情况。上机24h后，患儿心脏功能逐渐改善，我们在保证ECMO有效运行和患儿生命体征稳定的基础上，继续观察上述指标，并适当限制液体入量和速度、促进利尿，以每小时均速负平衡10～20ml为目标，尽量减轻循环负荷。随着患儿心脏功能的恢复，我们逐步降低ECMO流量，充分限制患儿液体入量，为ECMO撤机做好准备。

3.2.2　抗凝管理：血栓和出血是目前ECMO运行过程中最常见的并发症，也是导致患者死亡的主要原因之一[7]。因此，ECMO运行过程中需要恰当的抗凝，既要避免血栓的形成，又要防止过度抗凝引发出血。目前国内暂无统一的儿童ECMO抗凝管理方案，因此，对于该患儿的抗凝管理，我们借鉴成人管理经验，采用普通肝素进行抗凝，并动态监测活化凝血时间（activated clotting time，ACT）和活化部分凝血酶原时间（activated partial thromboplastin time，APTT）。在ECMO置管前，给予肝素2500　U静脉推注进行抗凝，5min后查ACT＞180s后进行置管。ECMO运行2h后，复查ACT和APTT，显示ACT168 s，APTT40.3 s，遂给予普通肝素5U/（kg·h）启动抗

凝治疗，然后每4h复查一次ACT，每8h复查一次APTT。并密切观察患儿瞳孔的变化情况、穿刺点周围渗血情况、皮下出血情况以及整个管路、氧合器、离心泵头内有无血栓形成。该患儿在ECMO运行期间，ACT波动在183-214 s，APTT波动在52-73.9 s，持续镇痛镇静的情况下瞳孔直径2mm，对光反射减弱，穿刺点周围及皮下均未见明显出血，也未见明显血栓形成。

3.2.3 呼吸机管理：根据《体外膜氧合支持儿科暴发性心肌炎专家共识》，ECMO建立后呼吸机以中等、半量支持条件设置[8]。在决定撤离ECMO之前，该患儿持续使用SIMV模式进行机械通气，潮气量设置为200mL/，FiO2设置为40%，呼吸频率设置为12次/分，PEEP 6.0cmH2O。并每4h监测一次血气分析，根据血气分析结果微调呼吸机参数，确保患儿处于酸碱平衡状态。当12月27日决定撤离ECMO时，一方面降低ECMO流量，另一方面将呼吸机参数设置如下：潮气量420mL/，FiO2设置为60%，呼吸频率设置为20次/分，PEEP 8.0cmH2O。ECMO撤离半个小时后复查血气分析，结果各指标均处于正常水平。

3.2.4 营养支持：研究表明，需ECMO支持的危重症患者易出现分解代谢增加、负氮平衡、胰岛素抵抗及营养输送不足，发生获得性营养不良风险增高。因此，准确评估ECMO支持患儿的营养状态，把握营养物质介入的方式和时机，是优化ECMO管理的关键环节[9]。患儿入院前食欲差，入院后查白蛋白为28.82g/L，

前白蛋白106.60 mg/L，故存在一定程度的营养不良。在患儿ECMO运行早期，因为需要补充血容量，多学科会诊后认为可以给予患儿一定量的肠外营养支持。所以在ECMO运行前48h，遵医嘱每天给予10g白蛋白静脉滴注，并辅以自制肠外营养制剂200ml/d静脉滴注，自制肠外营养制剂中总热卡为150 kcal/（kg· d），其中碳水化合物、蛋白质、脂肪配比为5:3:2，并适量添加其他营养元素，以保证患儿营养需求。48h后停止肠外营养，完全依靠肠内营养方式进行营养支持。与此同时，第一时间邀请营养科专家对该患儿的肠内营养方法进行指导。经过营养科专家评估，ECMO上机4h后为患儿留置鼻胃管，然后每6h鼻饲营养科根据患儿情况配置的匀浆膳50ml，24h后过渡到50ml/4h，逐步过渡到100ml/4h。24h内每次鼻饲前，床旁超声监测胃内容物潴留情况，确认无胃潴留或胃潴留 < 50ml时方可进行。整个肠内营养支持期间密切观察患儿消化吸收情况以及有无腹泻、腹胀等喂养不耐受等情况。

3.2.5 感染的预防：由于重症患儿的自身疾病基础、肠道菌群移位以及ECMO引起的免疫系统损伤和导管存在微生物定植等特点，患儿存在较高获得性院内感染的风险，威胁ECMO患儿的生命安全[10]，因此，应积极预防和控制院内感染的发生。该患儿ECMO上机后立即预防性使用了哌酮/舒巴来预防感染的发生，但预防性使用抗菌药物不能预防ECMO支持期间院内感染的发生。为此，我们将该患儿防置在单间病房，并在门口、床旁吊塔等位置配备了足量的快速手消，方便医务人员进行手卫生，从源头上降低患儿院内感染发生的可能性。同时，我们严格按照相关指南和规范，加强了对气管插管、导尿管、中心静脉导管及ECMO导管等三大导管的感染预防工作，避免因人为因素导致院内感染的发生。此外，基础护理的质量也在一定程度上影响着院内感染的发生。因此，在护理部的指导下，ECMO护理团队制定了周密的基础护理计划，包括眼部护理、口腔护理、氯已定溶液身体擦拭、皮肤护理等方面。经过所有医务人员的共同努力，该患儿住院期间未发生院内感染。

4 小结

儿童ECMO技术在国内尚处于起步阶段，整个运行过程极具挑战和复杂，对于管理团队的综合技术和协作能力要求极高，往往需要多个学科、多个专业、多个部门的大力协作[11]。本例患儿为急性暴发性心肌炎，病情进展急骤，多学科协作团队发挥各自优势，迅速展开救治，通过系列精细化管理，最终该患儿顺利脱离ECMO，康复出院。

参考文献

[1]徐伟仙,祖凌云.暴发性心肌炎治疗中体外膜肺氧合的应用及进展[J].中国急救医学,2021,41(07):616-620.

[2] Kociol RD,Cooper LT,Fang JC,et al.Recognition and initial management of fulminant myocarditis: a scientific statement from the american heart association[J]. Circulation,2020,141(6):e69-e92.

[3]周成斌,郭予雄,胡燕.中国儿科体外膜肺氧合技术的发展现状[J].中国临床新医学,2021,14(05):427-431.

[4] Amodeo I, Di Nardo M, Raffaeli G, et al. Neonatal respiratory and cardiac ECMO in Europe. Eur J Pediatr. 2021;180(6):1675-1692.

[5]陈容欣,史婧奕,任玉倩,等.体外膜氧合救治儿童爆发性心肌炎的临床疗效观察[J].中华医学杂志,2019,99(47):3715-3719.

[6]陈惠瑶,张莉,李杏崧,等.基于多学科协作模式应用体外膜肺氧合技术救治1例小儿急性暴发性心肌炎的护理[J].护理与康复,2021,20(10):59-61.

[7]杨保旺,洪小杨,封志纯.儿童体外膜肺氧合抗凝研究进展[J].中国小儿急救医学,2021,28(03):215-219.

[8]林茹,张晨美.体外膜氧合支持儿科暴发性心肌炎专家共识[J].中华急诊医学杂志,2020(01):36-37-38-39-40-41-42.

[9]曹佳颖,张育才,崔云.儿童体外膜肺氧合期间的营养管理策略[J].中华儿科杂志,2021,59(11):985-988.

[10]程东良,方柯南,邢燕,等.儿科体外膜肺氧合期间院内感染调查分析[J].中华实用儿科临床杂志,2021,36(18):1394-1397.

[11]刘成军,卢思为.儿童体外膜肺氧合技术应用现状和前景[J].西部医学,2020, 32(05):643-646.

Serum total bilirubin with hospital survival in adults during extracorporeal membrane oxygenation

Rui Huang1, Ming Shao1, Cheng Zhang2, Ming Fang1, Mengmeng Jin3, HAN Han1, Nian Liu1

1. Department of Critical Care Medicine, The First Affiliated Hospital of Anhui Medical University

2. Department of Anhui Provincial Cancer Institute, The first affiliated hospital of Anhui Medical University, Jixi Road 218, 230022, Hefei, China

3. Department of Respiratory and Critical Care, The Fourth Affiliated Hospital of Anhui Medical University,

Background Extracorporeal membrane oxygenator (ECMO) is widely used for refractory cardiopulmonary failure treatment. The disadvantage of ECMO is its higher risk profile and clinical resource consumption. This observation examines the role of serum total bilirubin (TBIL) as a predictor of adult patient outcomes on ECMO support.
Methods This retrospective observation reports a single center experience with adults on ECMO support between 2018 and 2021. Data were collected regarding demographics, ECMO details, laboratory parameters, and outcomes. We examined the elevation of TBIL to predict survival and variables associated with hyperbilirubinemia.
Results The patients who died within 28 days had a 2-fold higher peak level of TBIL than thosewho survived (73.10 [38.60, 98.64 vs. 34.50 [24.03, 54.85]; $P = 0.003$). Univariate logistic regression analyses demonstrated that high TBIL was remarkably associated with an elevated risk of 28-day mortality (OR: 7.25; 95% CI: 2.31~25.49; $P = 0.001$) and total mortality (OR: 5.71; 95% CI: 1.82~20.66; $P = 0.001$). The TBIL value was 65 μmol/L as the best cut-off value, and the observation group was divided into a high TBIL subgroup ($n = 21$) or a low TBIL subgroup ($n = 39$). The demographic and clinical features did not show a difference, whereas SOFA and APACHE II scores and ALT, AST and LAC before ECMO initiation correlated with high or low TBIL ($P < 0.05$). For coagulation function at the time of TBIL peaking, the levels of PT, APTT, PTA and FIB were different between the two subgroups ($P < 0.05$). The SOFA score was potentially associated with hyperbilirubinemia after ECMO initiation, and the prediction accuracy was 0.800.

Conclusion Serum total bilirubin elevation appears after ECMO initiation and correlates with survival, while other markers of liver injury do not. Serum total bilirubin is an easy-to-measure biomarker to be a predictor of survival after ECMO initiation.

Keywords: extracorporeal membrane oxygenator, total bilirubin, hyperbilirubinemia, survival, prognosis

Intensivist-led transportation of patients on extracorporeal membrane oxygenation: a single center experience

Nian Liu, Rui Huang, Yutao Zha, Min Shao, Wei Yang, Xuan Han
Department of Critical Care Medicine, The First Affiliated Hospital of Anhui Medical University

Objective The extracorporeal membrane oxygenation (ECMO) is considered to be the lifesaving strategy for patients suffering from refractory cardiac and respiratory failure. This study evaluated the feasibility, security and results from interhospital transportation by an intensivist-led team in China. Methods Eighty-two patients were transferred on ECMO between June 2018 and June 2021, and underwent retrospective analysis. ECMO circulation was performed by a four-person team of intensivists and nurse at peripheral hospital, mainly using percutaneous cannulation. Transport details, patient baseline characteristics, complications and survival were collected from medical records. Results Forty-one (50%) received veno-venous ECMO (VV-ECMO), and forty-one (50%) received veno-arterial ECMO (VA-ECMO). Eighty-one (98.8%) patients were transferred by ambulance, median distances of 109.0 km (74.5-213.0) for VV-ECMO and 171.0 km (45.0-213.0) for VA-ECMO. No deaths occurred during transport, patient related complications were 19% (16); cannula site bleeding (n=7, 8.5%) was the prominent; equipment related (n=12, 14.6%) requiring urgent interventions, hand cranking was the most common (9.7%). On-transport survival was 100%, and 36(43.9%) patients survived to hospital discharge. The ECMO weaning rate was 61% in VV-ECMO and 63.7% in VA-ECMO. ECMO complications, including bleeding requiring surgery, vascular surgery, cerebral vascular accident, ventilation, renal replacement therapy, blood transfusion, and new liver dysfunction, were not statistically significant. **Conclusions** The results show its feasibility, security with few on-transport complications and no mortality by an intensivist-led team. This may be a recommended staffing model for ECMO transferred in developing countries. Peripheral institutions may consider ECMO option at earlier stage for improving survival.

Keywords: extracorporeal membrane oxygenation, interhospital transport, complication, intensivist, survival

第6届中国医师协会体外生命支持年会
The 6th Chinese Society of ExtraCorporeal Life Support Annual Meeting

Analysis of risk factors affecting the prognosis of cardiogenic shock assisted by venous-arterial extracorporeal membrane oxygenation

Manli Sun, Rui Huang, Yutao Zha, Xuan Han, Ming Fang, Min Shao, Nian Liu
Department of Critical Care Medicine, The First Affiliated Hospital of Anhui Medical University

Objective: To explore the risk factors that affect the prognosis of cardiogenic shock (CS) assisted by venous-arterial extracorporeal membrane oxygenation (VA-ECMO).

Methods: This study retrospectively analysed 36 patients with CS who received VA-ECMO treatment over 24 hours from June 2018 to April 2021. The patients were divided into two groups: the survival group and the death group. The general clinical data, and laboratory indicators between the two groups were compared. Binary logistic regression analysis was used to screen the independent risk factors that affected the prognosis of CS assisted by VA-ECMO. A receiver operating characteristic curve (ROC) was drawn to evaluate the predictive value of each factor for the death of CS patients who received VA-ECMO treatment over 24 hours. Kaplan–Meier survival curves were used to compare in-hospital survival in patients with different lactate levels. Results: Univariate analysis showed that compared with the survival group, the death group had a longer duration of shock, a higher APACHE II score and vasoactive–inotropic score, a lower diastolic blood pressure, and a lower mean arterial pressure ($P<0.05$). Lower $HCO3^-$ levels and higher LDH levels were observed in the death group than in the survival group ($P<0.05$). There was no significant difference in the maintenance dose of norepinephrine before ECMO treatment in the two groups, but the dose was larger after 24 h of ECMO treatment in the death group. Higher levels of lactate and lactate dehydrogenase and lower lactate clearance rates before and after 24 h of ECMO treatment were detected in the death group than in the survival group. Logistic regression analysis showed that the lactate level after 24 h of ECMO treatment was an independent risk factor affecting prognosis. The area under the ROC curve (AUC) of lactate for predicting the risk of death in CS patients after 24 h of ECMO treatment was 0.800 ±0.157 (95% CI). The cut-off value of lactate was 2.11 mmol/L, with a sensitivity of 82.4% and specificity of 73.7%. Kaplan–Meier survival curves indicated that the survival rate of patients with lactate greater than 2.11 mmol/L was significantly lower than that of patients with lactic acid less than 2.11 mmol/L at 24 h after ECMO treatment (HR 0.154; 95%, CI 0.059-0.404; $P<0.001$)

Conclusion: CS patients assisted by VA-ECMO who experienced a longer duration of shock, higher lactate levels, a higher maintenance dose of norepinephrine after 24 h ECMO treatment, and a lower lactate clearance rate of 24 h, MAP and DBP were likely to have a poor prognosis. Lactate higher than 2.11 mmol/L after 24 h of ECMO treatment can be used as a predictive independent risk factor for the prognosis of these patients.

Key words: Cardiogenic shock; venous-arterial extracorporeal membrane oxygenation; risk factors; prognosis

Risk Factors associated with Nosocomial Infection in Patients during Extracorporeal Membrane Oxygenation

Background. Critically ill patients requiring extracorporeal membrane oxygenation (ECMO) are at high risk for developing nosocomial infections. The incidence, etiology, risk factors, and impact on outcome of nosocomial infections during ECMO remain controversary.

Methods. A retrospective observational study from January 2011 to December 2019 was performed and adult patients received ECMO support more than 48 hours were included in the study. The primary outcomes were incidence rate of ECMO-related infection. Clinical data were recorded and risk factors associated with increased risk of infection during ECMO were analyzed.

Results. A total of 174 adults patients received ECMO underwent 1670 ECMO-days were included in this study. 71 subjects (40.8%) developed ECMO related infections during their ECMO course, (61.1 infections/1,000 persondays of ECMO). In the multivariate Cox regression analysis, the factors independently associated with the infection during ECMO were higher SOFA score (HR = 3.153), lower lymphocyte count on D1 (HR = 0.066), lower platelet count on D2 (HR = 0.933) and higher DeltaFib (HR = 2.936). Of 71 infected patients during ECMO, 45(63.4%) had died. There was no significant difference on mortality between infected patients and non-infected patients during ECMO(P=0.08), but in the infected patients with septic shock showed a significantly higher mortality rate than without septic shock(P<0.001). MDR bacteria were not significantly associated with an increased risk of death (P=0.981).

Conclusions. Our findings suggest that higher SOFA score, lower lymphocyte count and coagulation dysfunction were significantly associated with an increased risk of infection during ECMO. The ECMO-related infection patients did not have an impact on mortality， but the infected patients with septic shock during ECMO showed a significantly higher mortality rate than without septic shock.

Key words: extracorporeal membrane oxygenation; nosocomial infection; risk factors; intensive care unit; mortality

第6届中国医师协会体外生命支持年会
The 6th Chinese Society of ExtraCorporeal Life Support Annual Meeting

血管活性药物-正性肌力药物评分及乳酸与成人心脏术后VA-ECMO患者的预后

田夏秋 王粮山 李呈龙 杨峰 邵涓涓 王红 贾明 侯晓彤
首都医科大学附属北京安贞医院心脏外科危重症中心

目的 乳酸及血管活性药物-正性肌力药物评分（VIS）与成人心脏术后VA-ECMO患者住院死亡率相关，但受血管张力等影响，单使用VIS或乳酸来预测预后存在局限。本研究旨在明确联合使用VIS及乳酸与成人心脏外科术后VA-ECMO患者预后的关系。

方法 回顾性收集北京安贞医院2015.1-2018.12心脏外科术后行VA-ECMO辅助的成人患者共222例，根据ECMO上机前VIS及乳酸（Lac）的ROC曲线cutoff值分为四组，组1：VIS≤24.3、Lac≤6.85 mmol/L；组2：VIS≤24.3、Lac>6.85 mmol/L；组3：VIS>24.3、Lac≤6.85 mmol/L；组4：VIS>24.3、Lac>6.85 mmol/L。分析四组住院死亡率等临床结局发生率，Cox回归分析VIS及乳酸与住院死亡率的关系。

结果 四组分别纳入69、71、31、51名患者，四组患者的中位年龄分别为62岁、68岁，66岁、66岁（p=0.042）。四组的住院死亡率分别为37.7%、50.7%、54.8%及76.5%（p<0.001），ECMO成功脱机率分别为73.9%、69%、61.3%及39.2%（p=0.001）；中位住院时间分别为21天、18天、22天和15天（p=0.001）；多脏器功能衰竭发生率分别为21.7%、36.6%、41.9%及49%（p=0.016）。Cox回归结果显示年龄（HR 1.03）、女性（HR 1.50）、VIS>24.3（HR 1.91）及乳酸>6.58mmol/L（HR 1.60）为住院死亡率的独立危险因素。

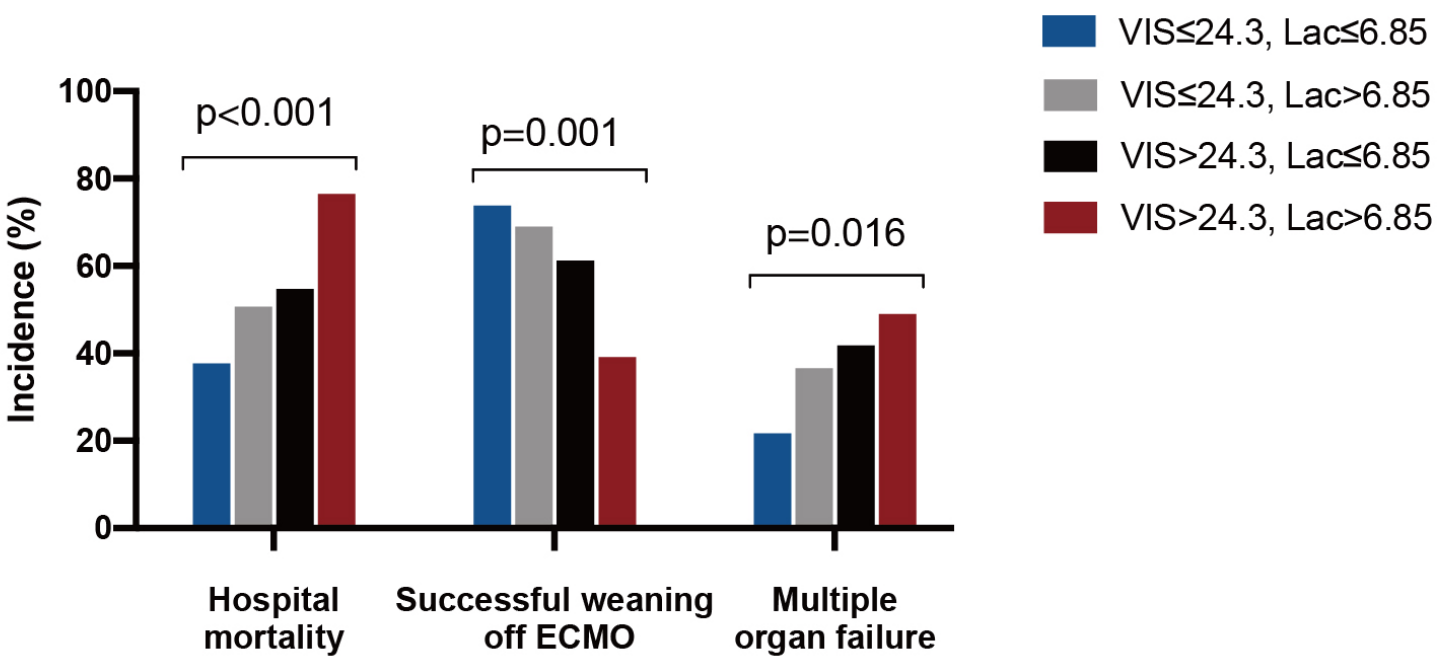结论 ECMO上机前VIS>24.3且乳酸>6.85 mmol/L患者住院死亡率显著提高，成功撤机率明显降低，年龄、女性、VIS>24.3及乳酸>6.85 mmol/L是住院死亡的独立危险因素。